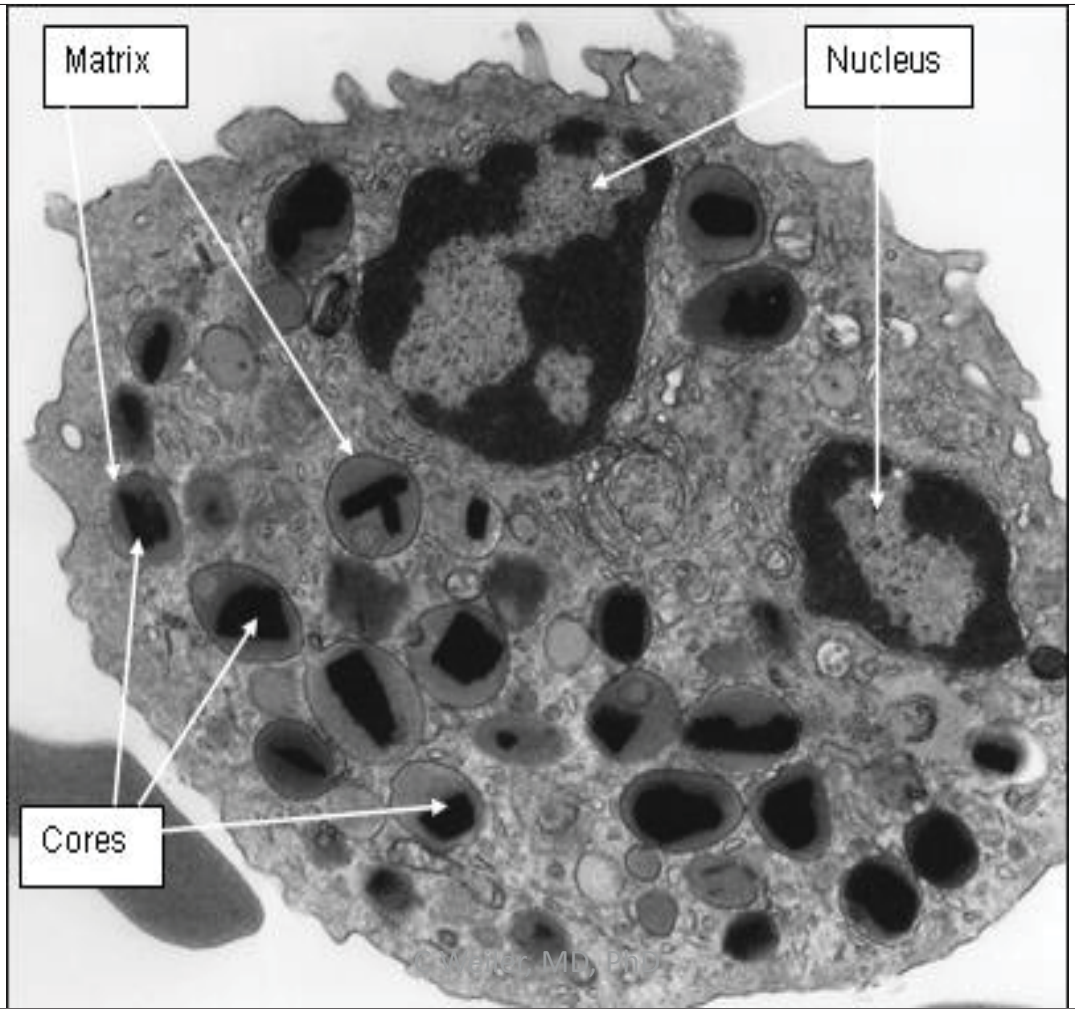

Eosinophilia and Related Disorders

Catherine Weiler, MD, PhD
Co-Chair, Mayo Clinic Program for the Study of Mast Cell and Eosinophil Disorders
Division of Allergy
Mayo Clinic, Rochester, MN

Disclosures

NOTHING TO DISCLOSE

Objectives

- Eosinophilia to hypereosinophilic syndrome, what is the difference?
- What next?
- Eosinophilic esophagitis (EoE), diagnosis and management

My Current Presentation Goals

- Review two eosinophil disorders
  - Hypereosinophilic Syndrome (HES)
  - Eosinophilic Esophagitis (EoE)
- Finish within 45 minutes

Question 1.

- Reactive eosinophilia is secondary to all the listed disorders **except** one:
  - A Rheumatoid arthritis
  - B Parasite infections
  - C Natural supplements
  - D Hypoadrenalism
  - E Mastocytosis
  - F Hyperadrenalism

Patient 1.

- 43-year-old white male
- Went to ER asking for help with dyspnea and precordial chest pain
- WBC 17.0 cells/ μL with 55% eosinophils; ESR 38
- CT chest: pericardial and pleural effusions
- ECHO: tamponade
- Pericardiocentesis: 600 mL removed with >1,000 cells/mL 18% eosinophils

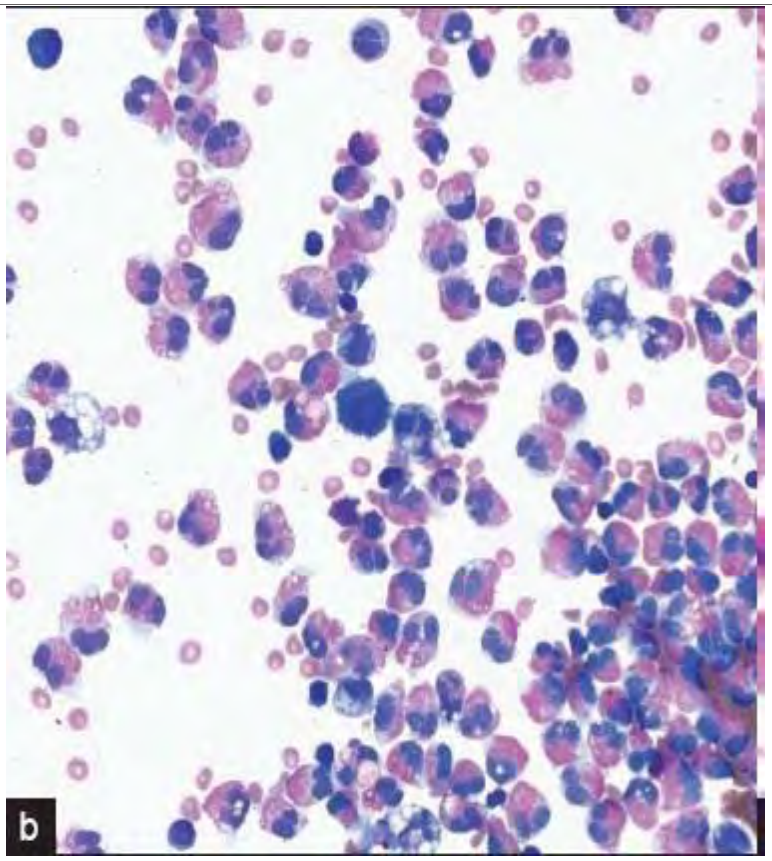

Digestive Diseases and Sciences, 2003; 48:1013–1020

Patient 1.

- Subsequently he developed arthralgia and arthritis
- Blood tests: Cyclic citrullinated peptide (CCP) 33.8 (normal <20) highly specific for RA
- Diagnosed with rheumatoid arthritis
- Methotrexate normalized eosinophil count
- He is now off steroids unless he skips MTX

Eosinophilia and RA

- One hundred nine patients were included, 95 women
- Eight patients (7.33%) showed eosinophilia
- Patients with eosinophilia had a higher Sed Rate, dry mouth, anal pruritus, and paresthesia
- Most of the patients with eosinophilia have parasite infections

» Prevalence and Clinical Significance of Eosinophilia in Patients With Rheumatoid Arthritis in Argentina *J Clin Rheumatol* 2008;14: 211–213

Eosinophilia and RA

- 26 of 804 (3.2%) of RA patients had eosinophilia (mean eosinophil count , 637.7±107/mm3)
- At 3 years after the diagnosis, patients with eosinophilia had worse disease activity (0.9 vs 0.5, p=0.004), worse visual analogue scale activity score and morning stiffness intensity (p=0.05), and were more often taking disease-modifying agents (p=0.02)
- Baseline eosinophilia was not associated with presence of extra-articular manifestations

» Guellec D, Milin M, Cornec D, et al. Eosinophilia predicts poor clinical outcomes in recent-onset arthritis: results from the ESPOIR cohort RMD Open 2015;1:e000070. doi:10.1136/rmdopen-2015-000070

Question 2.

- The percentage of thrombosis in patients with HES is:
  - 0%
  - 20%
  - 5%
  - 2%

Patient 2.

- 47-year-old white male with 3 weeks of bilateral hand numbness, tingling, severe pain and new onset lower extremity edema
- Both hands were cyanotic, dusky, cold and exquisitely tender. Radial and left popliteal pulses were not palpable
- WBC 20.3K, eosinophils 10.9K, platelets 8K

» Clin Adv Hematol Oncol. 2013;11:317-9

Patient 2. Initial Arteriogram

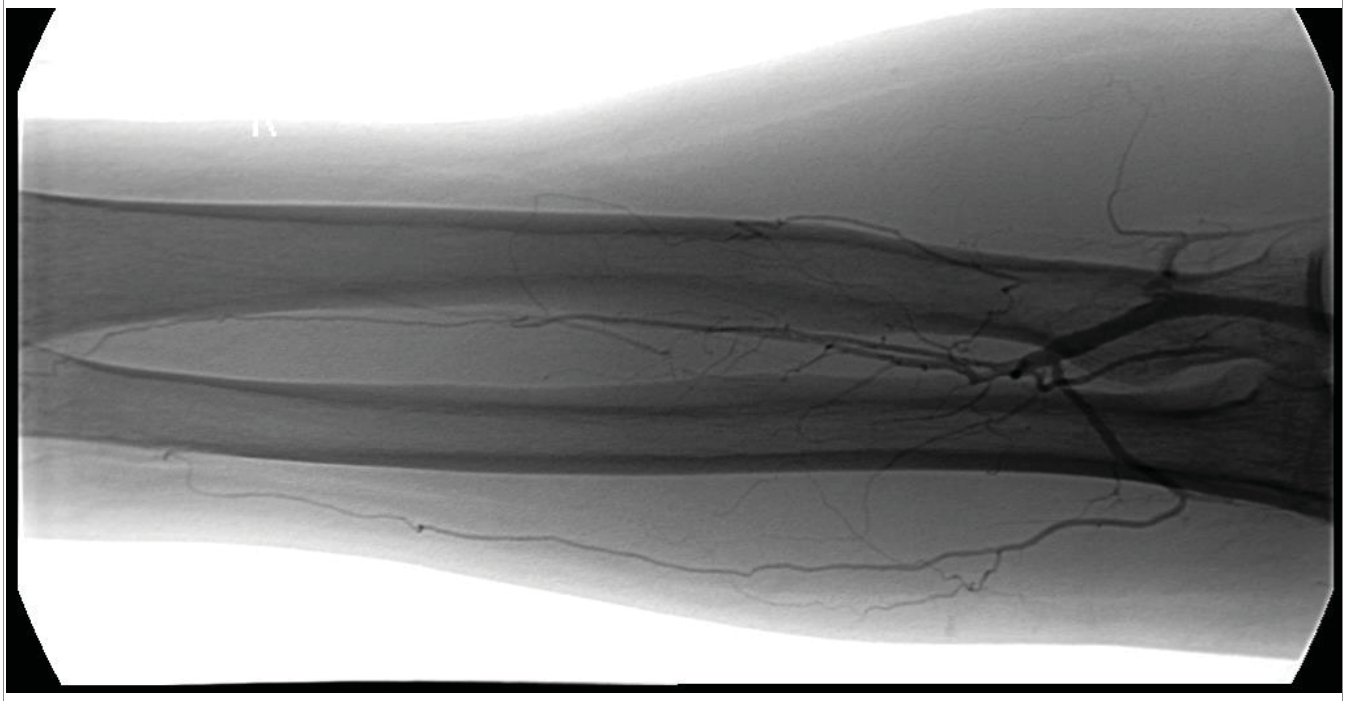

Patient 2. Initial Arteriogram



Patient 2

- After thrombectomies, IV steroids and heparin the platelet and eosinophil counts normalized
- Once prednisone was tapered, at 20 mg/d, he developed chest pain, eosinophilia and thrombocytopenia
- Two subsequent attempts to taper prednisone failed and arterial thrombosis developed
- Interferon-α and hydroxyurea failed as steroid-sparing agents

Clin Adv Hematol Oncol. 2013;11:317-9 Leon-Ferre RA et. al.

Patient 2. Post Thrombectomies

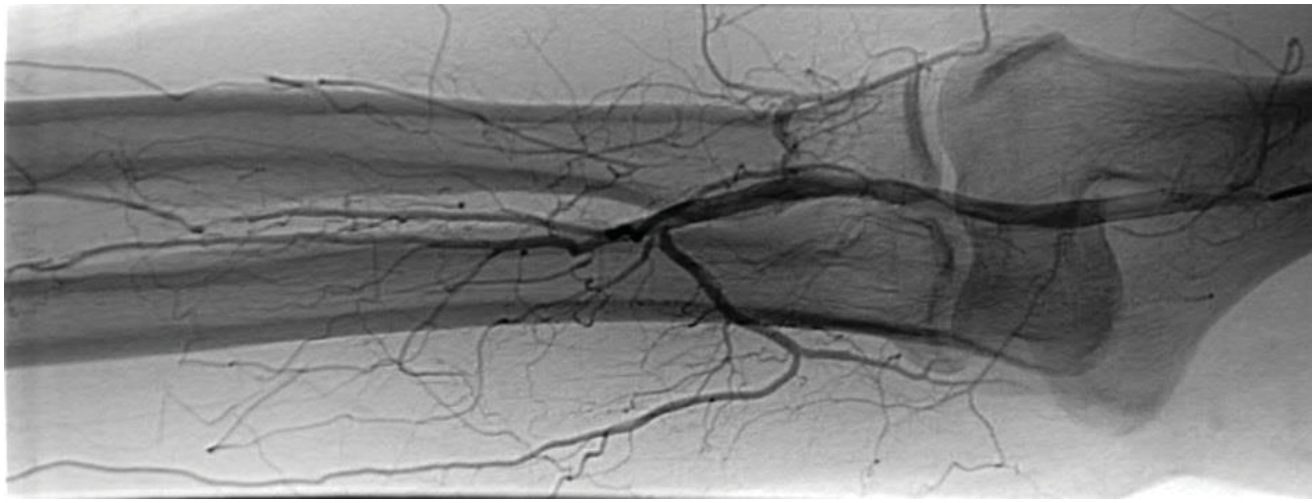

Patient 2.

- Bilateral index finger necrosis followed by amputation
- Seven months from diagnosis, therapy with anti-IL-5 was started
- Today, about 10 years from presentation, he continues to have severe peripheral ischemic pain
  - » Clin Adv Hematol Oncol. 2013;11:317-9 **Hypereosinophilic syndrome presenting as an unusual triad of eosinophilia, severe thrombocytopenia, and diffuse arterial thromboses, with good response to mepolizumab.** Leon-Ferre RA[1], Weiler CR, Halfdanarson TR

Extensive Digital Gangrene Without Evidence of Large-vessel Occlusion in Hypereosinophilic Syndrome

Taegyun Kim, Mi Ri Kim, Jong Hoon Kim, Hyunjoong Jee and Soo-Chan Kim*

Hypereosinophilia Presenting as Eosinophilic Vasculitis and Multiple Peripheral Artery Occlusions without Organ Involvement

Eosinophilia and Thrombosis

- PLoS One. 2015 Nov 5;10(11):e0142167. doi: 10.1371/journal.pone.0142167. eCollection 2015. **Unfavorably Altered Fibrin Clot Properties in Patients with Eosinophilic Granulomatosis with Polyangiitis (Churg-Strauss Syndrome): Association with Thrombin Generation and Eosinophilia.** Mastalerz L[1], Celińska-Löwenhoff M[1], Krawiec P[2], Batko B[2], Tłustochowicz W[3], Undas A[4]

Patient 3.

- 40-year-old Spanish female presented with *intermittent chest pain*
- Her past history was significant for:
  - 7 months prior to presentation she visited El Salvador where she was around chickens, ducks, turkeys, and dogs
  - 3 months ago she developed *diarrhea, abdominal pain, nausea and vomiting* and lost 12 pounds
- Her main concern was dying

Patient 3.

- She was unable to walk more than three steps before having to stop because of shortness of breath and fatigue
- Peripheral cyanosis noted
- Cardiac exam abnormal
- Hypereosinophilia was noted

Patient 3.

- ECHO: Large thrombus in LV and smaller thrombus in the RV
- Treatment with High dose steroids, aspirin, warfarin, and metoprolol was instituted
- Two different courses of ivermectin as well
- Cardiac surgeons evaluated and planned decortication
- Patient survived cardiac surgery with no neurologic deficits

Patient 3.

- 16-JAN-2012 STOOL O&P no Parasites seen
- 18-JAN-2012 STOOL O&P no parasites seen
- 23-JAN-2012 STOOL FINAL: **STRONGYLOIDES STERCORALIS LARVA**

Part 1.

EOSINOPHILIA vs. HES

Eosinophil Disorders

Condition	Proposed Abbreviation	Definition and Criteria
Blood Eosinophilia	-	>0.5 Eosinophils × 10^9/L blood
Hypereosinophilia	HE	>1.5 Eosinophils × 10^9/L blood on 2 examinations (interval ≥1 month) and/or tissue HE defined by the following: 1.Percentage of eosinophils in BM section exceeds 20% of all nucleated cells and/or 2.Pathologist is of the opinion that tissue infiltration by eosinophils is extensive and/or 3.Marked deposition of eosinophil granule proteins is found (in the absence or presence of major tissue infiltration by eosinophils).

Contemporary consensus proposal on criteria and classification of eosinophilic disorders and related syndromes. AU Valent, et. al. J Allergy Clin Immunol. 2012;130(3):607. 2012

Eosinophil Disorders

Condition	Proposed Abbreviation	Definition and Criteria
Hypereosinophilic Syndrome	HES	1.Criteria for peripheral blood HE fulfilled <u>and</u> 2.<u>Organ damage</u> and/or dysfunction attributable to tissue HE <u>and</u> 3.Exclusion of other disorders or conditions as major reason for organ damage.
Eosinophil-associated single-organ diseases	-	1.Criteria of HE fulfilled and 2.Single-organ disease (Listed in reference)

Contemporary consensus proposal on criteria and classification of eosinophilic disorders and related syndromes. AU Valent , et. al. J Allergy Clin Immunol. 2012;130(3):607. 2012

Am J Hematol. 2015 Nov;90(11):1077-89 Gotlib J

WORLD HEALTH ORGANIZATION-DEFINED EOSINOPHILIC DISORDERS: 2015 UPDATE ON DIAGNOSIS, RISK STRATIFICATION, AND MANAGEMENT

HES Presenting Symptoms & Labs

Symptoms

- Asymptomatic
- Weakness & fatigue 26%
- Cough 24%
- Dyspnea 16%
- Myalgias or angioedema 14%
- Rash or fever 12%
- Rhinitis 10%

Labs

- Eosinophilia 1,500-400,0000/cc
- Anemia 53%
- Thrombocytopenia 31%
- Thrombocytosis 16%
- Bone marrow eosinophilia
  - Mean 33% (7%-57%)
  - Charcot Leyden crystals, fibrosis, blasts

HES

Myeloid

- Male predominance
- Hepatosplenomegaly
- Mucosal ulcers
- Endomyocardial fibrosis
- High B12 levels
- Possible high tryptase
- Possible progression to eosinophil leukemia

Lymphocytic

- Skin manifestations, LN 62%; rheumatol 29%; GI 24%; lung 19%; CNS 10% and cardiovascular 5%
- Usually an indolent disease but may transform to Sezary or T-cell lymphoma
- Accompanied by cytogenetic changes.

HES

Myeloid

- Increased eosinophils, neutrophils or monocytes
- Anemia, thrombocytopenia, blasts, circulating myeloid precursors
- Increased BM cellularity
- FIP1L1-PDGFRA, PDGFRB, or FGFR1
- The fusion gene is present in multiple lineages (neutrophils, mast cells, T cells, B cells) as well as eosinophils.

Lymphocytic

- Polyclonal eosinophil expansion
- Abnormal surface phenotype:
  - Absence of CD3: $CD3^{-}CD4^{+}$ or
  - Double negative immature T cells: $CD3^{+}CD4^{-}CD8^{-}$
- T-cell receptor gene re-arrangement- on the BM
- Clonality present in up to 40% of patients accompanied by an abnormal phenotype or abnormal cytokine production in order to qualify as L-HES.

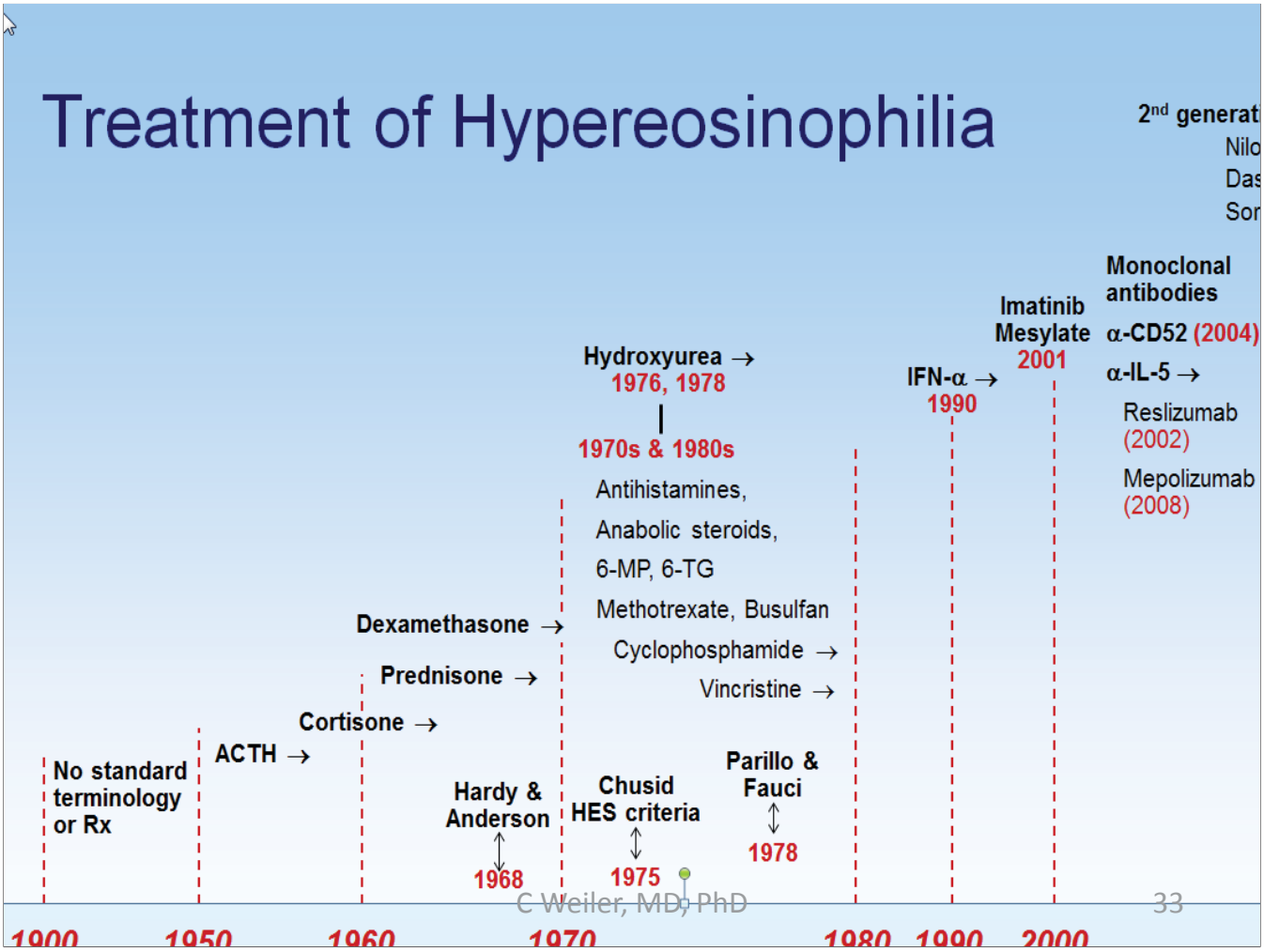

HES Treatment

Myeloid

- Resistant to steroids
- PDGFRB fusion genes are sensitive to Imatinib mesylate: 100-400 mg/d (or less)
  - M-HES is much more sensitive to Imatinib than is CML.
  - Be sure to check Troponin-T before treating with Imatinib. To be extra safe also treat with prednisone for first 10d even is troponin T is normal.
- FGFR-1 are resistant to TKIs

Lymphoid

- Treat as you would "regular" HES
  - Prednisone
  - Best to avoid if possible: IFN-α* caution-has anti-apoptotic activity on the abnormal T-cells;
  - 1 case of lymphoma in IFN- α treated L-HES
    - Roufosse F et al. **Lymphocytic variant HES syndrome progressing to angioimmunoblastic T-cell lymphoma**. *Leukemia & Lymphoma 2015; 56: 1881*

Current Therapies for Refractory HES

- **Tyrosine Kinase Inhibitors** such as imatinib mesylate, nilotinib or Sorafenib
- **Monoclonal antibody** therapy
  - Mepolizumab (anti-IL-5)
  - Reslizumab (anti-IL-5)
  - Benralizumab (anti-IL5 receptor)
  - Alemtuzumab (anti-CD52)
    - N Engl J Med. 2017 May 22. doi: 10.1056/NEJMoa1703501
    - J Am J Hematol. 2015 ;90:1077-89
    - Blood 2004; 103: 2939
    - J Allergy Clin Immunol. 2012;130:563-71
    - Clin Lymphoma Myeloma Leuk. 2013; 13:287-91

Second Part

EoE

Question 3.

- 25-year-old white male with severe depression is in your office. His seasonal allergies and bronchial asthma are under good control and stable. His only complaint today is odynophagia. You refer him to a gastroenterologist who performs an EGD. She sees the following:

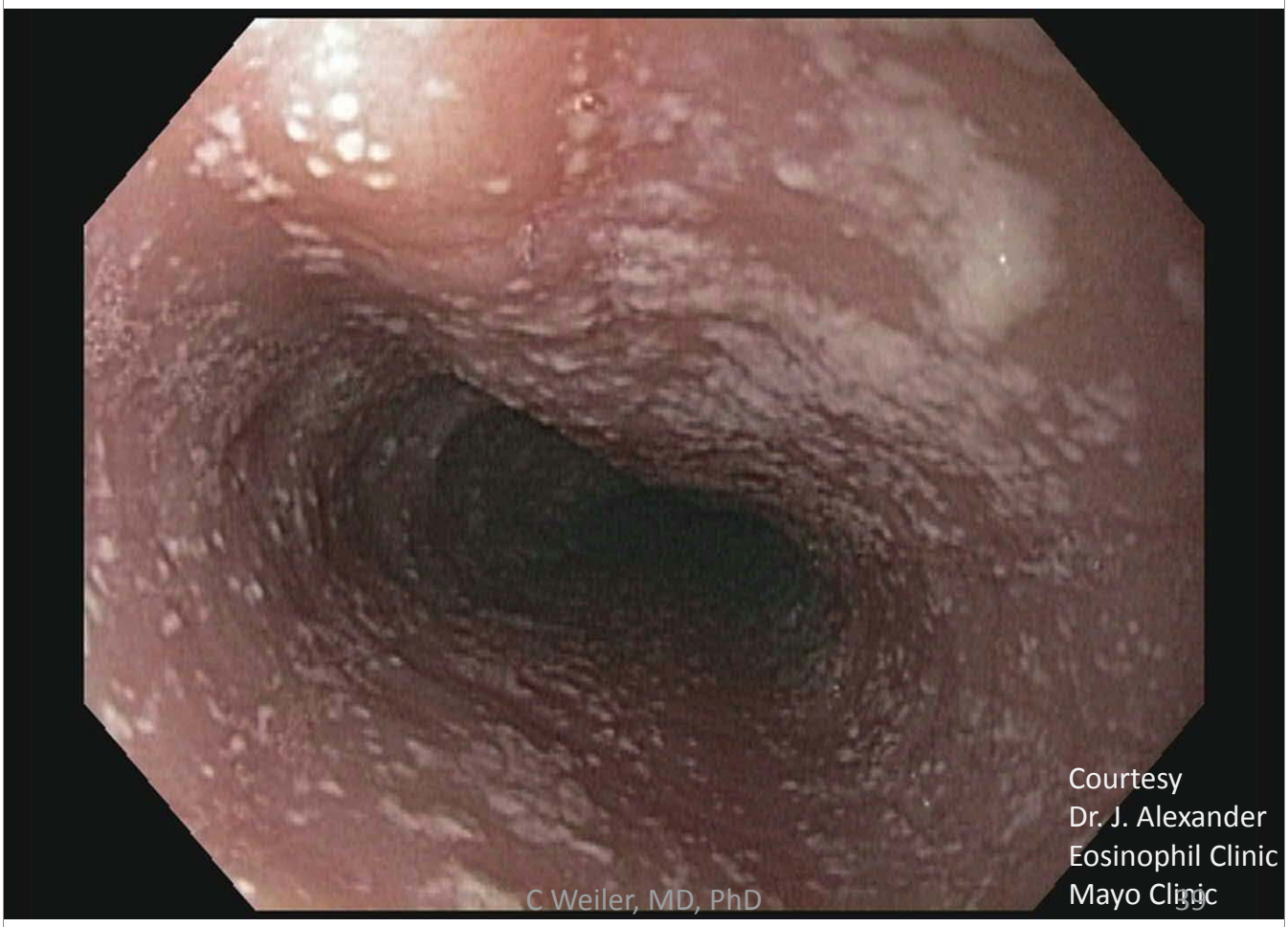

What is your diagnosis?

- Choose only one answer:
  - 1 Esophageal candidiasis
  - 2 Chemical injury from past suicide attempt
  - 3 Eosinophilic esophagitis
  - 4 She showed you the wrong picture that couldn't be your patient

Question 4.

- The six food avoidance diet includes avoidance of (choose one answer):
  - 1 Milk, wheat, egg, soy, tree nuts/peanuts, and fish/shellfish
  - 2 Milk, beef, wheat, egg, soy, and tree nuts/peanuts
  - 3 Milk, wheat, beef, soy, tree nuts/peanuts, and fish/shellfish
  - 4 Milk, wheat, egg, beef, tree nuts/peanuts, and fish/shellfish

1977 New Haven Connecticut

GASTROENTEROLOGY 72:1312–1316, 1977

Vol. 72, No. 6
Printed in U.S.A.

EOSINOPHILIC GASTROENTERITIS WITH ESOPHAGEAL INVOLVEMENT

JOHN W. DOBBINS, M.D., DANIEL G. SHEAHAN, M.B., M.SC., AND JOSE BEHAR, M.D.

Department of Internal Medicine and Pathology, Yale University, New Haven, Connecticut, and The West Haven Veterans Administration Hospital, West Haven, Connecticut

A patient with a lifelong history of asthma and hay fever was investigated because of symptoms of esophageal spasm. Esophageal biopsies revealed elongated papillae and basal zone hyperplasia of the epithelial layer with eosinophilic infiltration of the lamina propria and muscularis mucosae. There was no evidence of reflux. Small bowel biopsies revealed a flat mucosal pattern with absent or blunted villi, tall columnar surface epithelium, and eosinophilic infiltration of the lamina propria. He did not respond to a gluten-free diet. This patient is thought to have eosinophilic gatroenteritis with esophageal involvement, the first such case reported.

Eosinophilic Esophagitis

Daniel Picus[1] and Paul H. Frank[1]

Eosinophilic gastroenteritis is an uncommon disease usually involving the stomach and small intestine. It is characterized by peripheral eosinophilia, infiltration of the gastrointestinal tract by eosinophils, and clinical symptoms related to the site of involvement. In addition, up to 50% of patients may have either an allergic history or one of specific food intolerance [1–4].

While it has been well described radiologically in the stomach and small bowel, eosinophilic involvement of the esophagus is rare and the radiologic manifestations have not been described [5, 6]. We report a case of eosinophilic esophagitis and discuss its radiologic manifestations.

Case Report

A 16-year-old boy was evaluated for a 1½ year history of progressively worsening dysphagia. He complained of a sensation of food sticking at the level of his sternal notch, which was relieved by vomiting. His health had previously been excellent and his only allergy was to penicillin. He denied odynophagia, asthma, specific food tolerance, or history of drug or caustic ingestion. Physical

resolving, but the patient still had to chew his food thoroughly and use fluids to assist swallowing.

The patient was seen again 3 weeks later while still on prednisone, 30 mg/day. Endoscopy at that time showed a postinflammatory stricture at 23 cm with a normal-appearing mucosal pattern. Biopsy from the region of the stricture showed normal squamous mucosa. Pertinent laboratory data included 0% eosinophilia. The patient underwent a series of dilatations of the strictured area with excellent clinical results.

Discussion

Eosinophilic gastroenteritis is usually found in the stomach or small bowel. Its clinical presentation has been correlated with the particular layer it involves [2–4, 7–9]. Mucosal disease in these areas may be associated with malabsorption and blood loss. Muscularis involvement is associated with obstruction, and serosal disease can result in eosinophilic ascites. These various forms may be seen alone

American Journal of Roentgenology, 1981 136:1001-3
University of Chicago

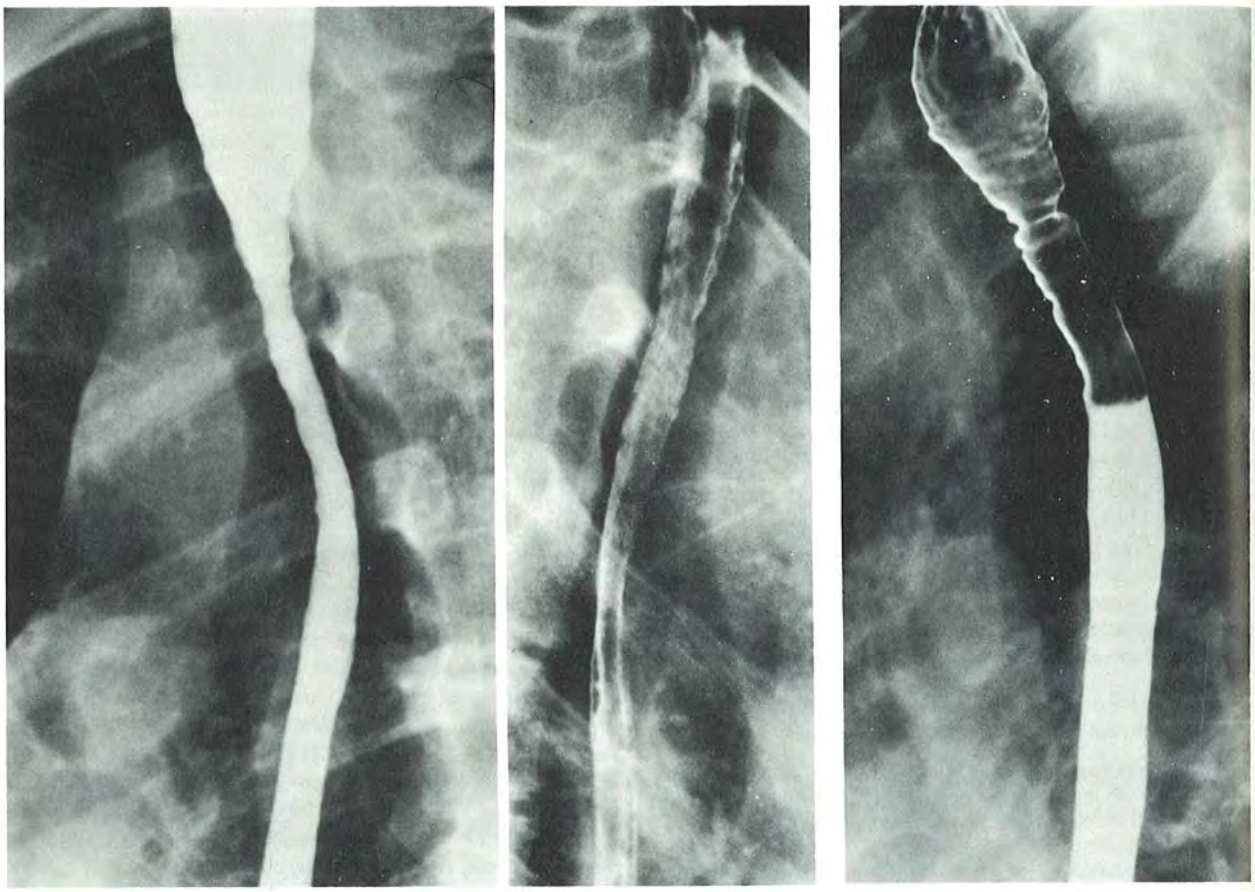

Fig. 1.—**A,** Esophagram, upper esophagus. A 6 cm stricture with diffuse narrowing and surface irregularity. **B,** Double contrast view of same area. Nodularity and fine superficial ulcerations.

Fig. 2.—Double contrast esophagram. Ring-like stricture at proximal part of diseased area. Some lack of distensibility also seen 3 cm distally.

Esophageal Eosinophilia with Dysphagia

A Distinct Clinicopathologic Syndrome

STEPHEN E.A. ATTWOOD, MB, FRCS, THOMAS C. SMYRK, MD, TOM R. DEMEESTER, MD, and JAMES B. JONES, PharmD

Small numbers of intraepithelial esophageal eosinophils (IEE) may be seen in 50% of patients with gastroesophageal reflux disease and occasionally in normal volunteers. High concentrations of IEE are rarely seen in either setting. During a two-year period we identified 12 adult patients with very dense eosinophil infiltrates in esophageal biopsies (defined as >20 IEE/high-power field). Dysphagia was the presenting complaint in each, but no evidence of anatomical obstruction could be found. Endoscopic esophagitis was absent, but biopsy showed marked squamous hyperplasia and many IEE. Eleven patients had normal esophageal acid exposure on 24-hr pH monitoring. Esophageal manometry showed a nonspecific motility disturbance in 10 patients. For comparison, 90 patients with excess esophageal acid exposure on 24-hr pH monitoring were studied. Thirteen (14%) had motility disturbance, and 21 (23%) had dysphagia. Esophageal biopsies were devoid of IEE in 47 patients; none of the 43 with IEE had infiltrates as dense as those seen in the 12 study patients. The presence of high concentrations of IEE in esophageal biopsies from patients with dysphagia, normal endoscopy, and normal 24-hr esophageal pH monitoring represents a distinctive clinicopathologic syndrome not previously described.

Digestive Diseases and Sciences 1993, 38:109- Creighton University
IEE: Intraepithelial Eosinophils 12 adults mostly male >20 eosinophils/ HPF

EoE Definition

American

- " EoE is an antigen driven disorder whose symptoms and pathology are responsive to either dietary control or steroid therapies. Gene expression is different between EoE and GERD"

- *Annu Rev Pathol.* 2016 23;11:365-93. Davis and Rothenberg

European

- "Eosinophilic esophagitis (EoE) represents a chronic, local immune-mediated esophageal disease, characterized clinically by symptoms related to esophageal dysfunction and histologically by eosinophil-predominant inflammation"
- *United European Gastroenterol J.* 2017 Apr;5(3):335-358.

EoE Definition & Diagnosis

American

- Males, atopy, food sensitivity
- Food impaction
- Neutral pH probe
- Endoscopic furrowing and rings
- Proximal and distal disease
- Epithelial hyperplasia
- Annu Rev Pathol. 2016 23;11:365-93. Davis BP[1], Rothenberg ME[2]

European

- Male of any age
- 23% and 50% in patients with dysphagia and food impaction
- Spectrum from GERD to EoE

United European Gastroenterol J. 2017 Apr; 5(3):335-358. Lucendo AJ et. al.

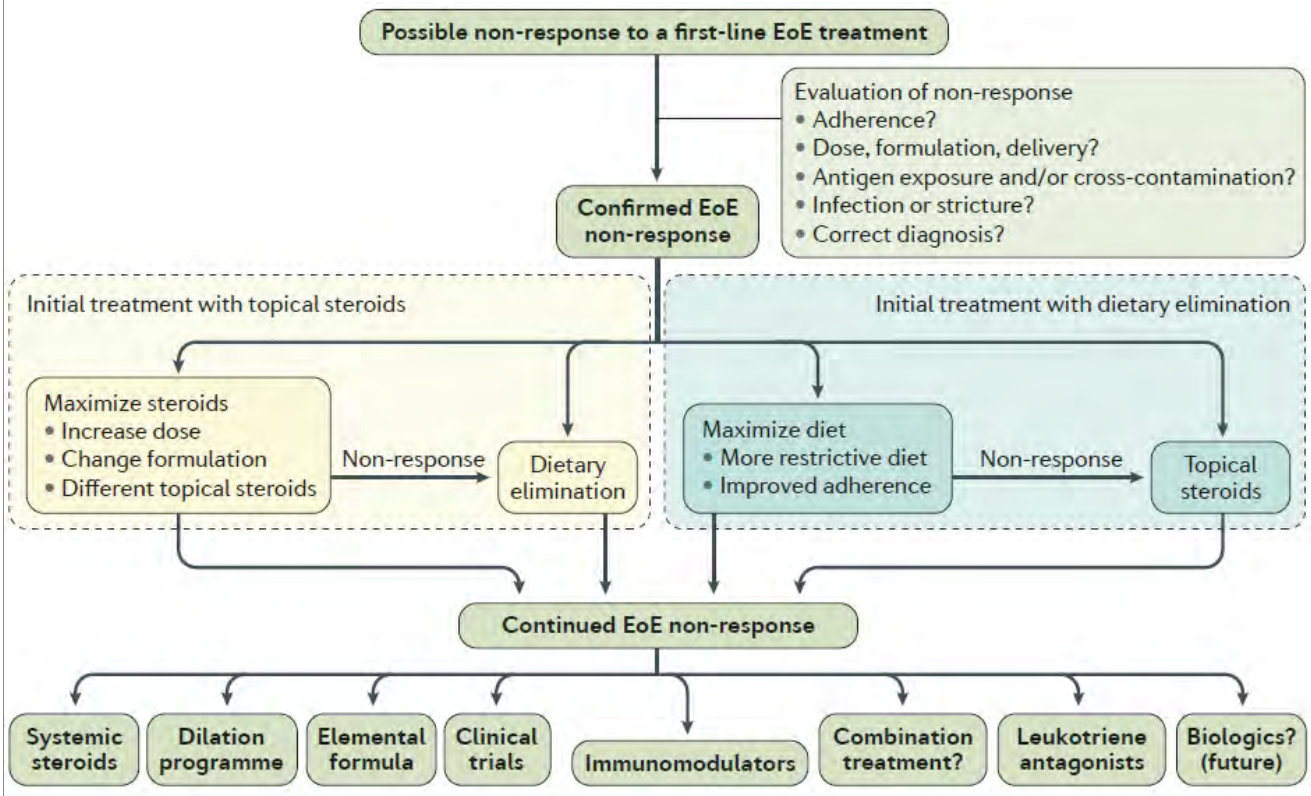

Nat Rev Gastroenterol Hepatol. 2017 May 24 **Management of refractory eosinophilic oesophagitis** Dellon ES

Does Response to PPI Therapy Rule Out EoE?

- Adult patients achieving clinical and histological remission on PPI therapy are part of the EoE continuum, rather than a separate entity.
- Responders and non-responders to PPI therapy show overlapping phenotypic, genetic, and mechanistic features
- EoE and GERD are different entities and may coexist, either unrelated or interacting bi-directionally.

» *United European Gastroenterol J.* 2017 Apr;5(3):335-358.
» *Annu Rev Pathol.* 2016 23;11:365-93. Davis BP and Rothenberg

EoE Diagnosis

- ≥ **Six biopsies** from different locations
- EoE =**15 eosinophils per high power field** in esophageal mucosa, taken as the peak concentration in the specimens examined.
- Eosinophil microabscesses, basal zone hyperplasia, dilated intercellular spaces, eosinophil surface layering, papillary elongation, and lamina propria fibrosis

» *United European Gastroenterol J.* 2017 Apr; 5(3):335-358.

Prognosis

- Untreated EoE is usually associated with persistent symptoms and inflammation, leading to esophageal remodeling resulting in stricture formation and functional abnormalities. There is some evidence that effective anti-inflammatory treatment may limit progression

» *United European Gastroenterol J.* 2017 Apr; 5(3):335-358.

Diet Elimination Therapies

- A **six-food** elimination diet induces histologic remission in around **¾** of EoE patients
- A **four-food** elimination diet achieves remission in **½** of EoE patients
- A **two-food** elimination diet (animal milk and gluten-containing cereals) may be still effective in **2/5th** of patients
- Prolonged avoidance may lead to drug-free sustained clinical and histological remission

Therapeutic Regimens

- **PPI therapy** induces clinical and histological remission in a proportion of patients with EoE and long-term PPI therapy maintains remission
- **Topical corticosteroids** are effective for induction of histological remission and long-term therapy with topical corticosteroids maintains remission in a proportion of patients
- **Esophageal candidiasis**, mostly incidental, may occur in up to 10% of patients

» *United European Gastroenterol J.* 2017 Apr; 5(3):335-358.

Is There a Role for Gastroenterologists?

- Endoscopic dilation improves dysphagia in up to ¾ of adult EoE patients with reduced esophageal caliber
- Dilatation does not reduce the underlying esophageal inflammation
- The risk of esophageal perforation smaller than 1%

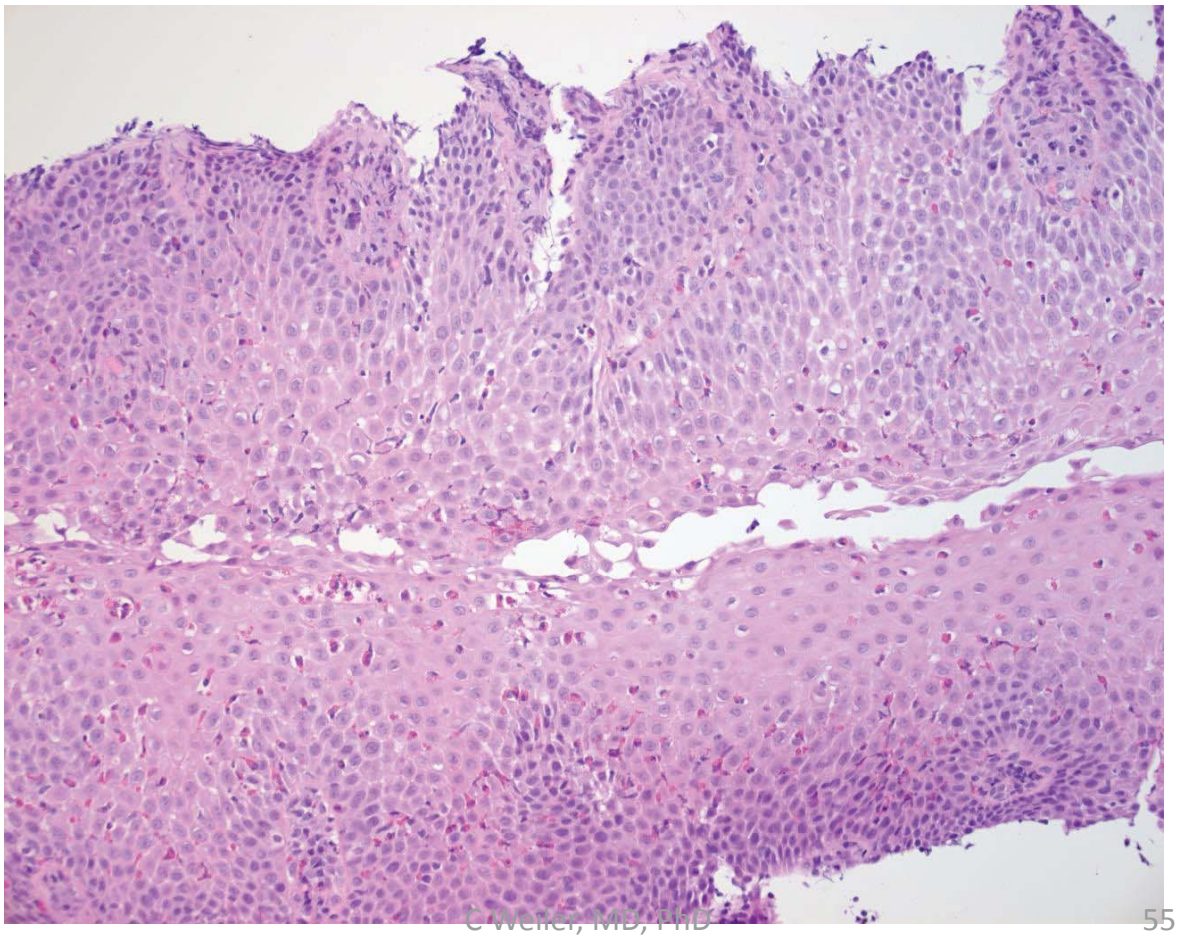

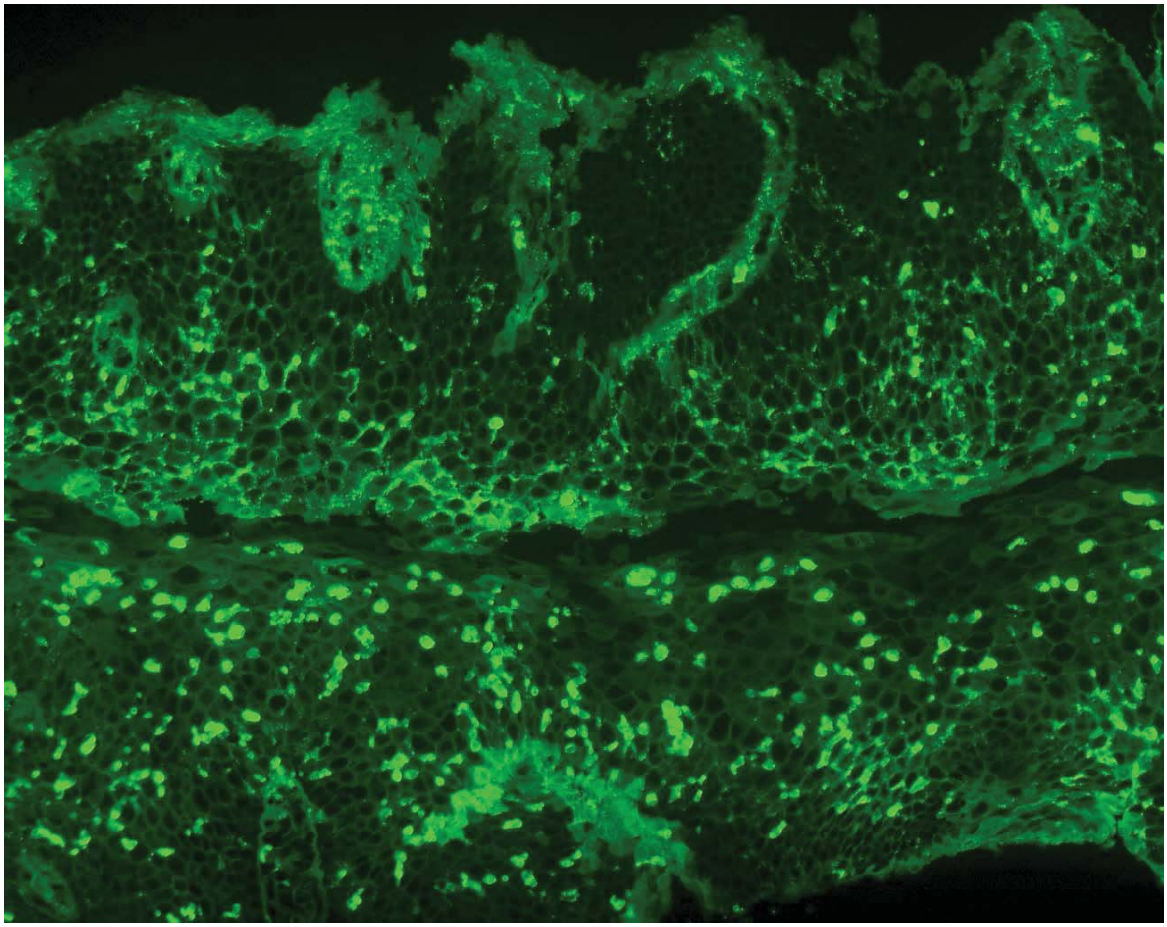

Anti-EDN

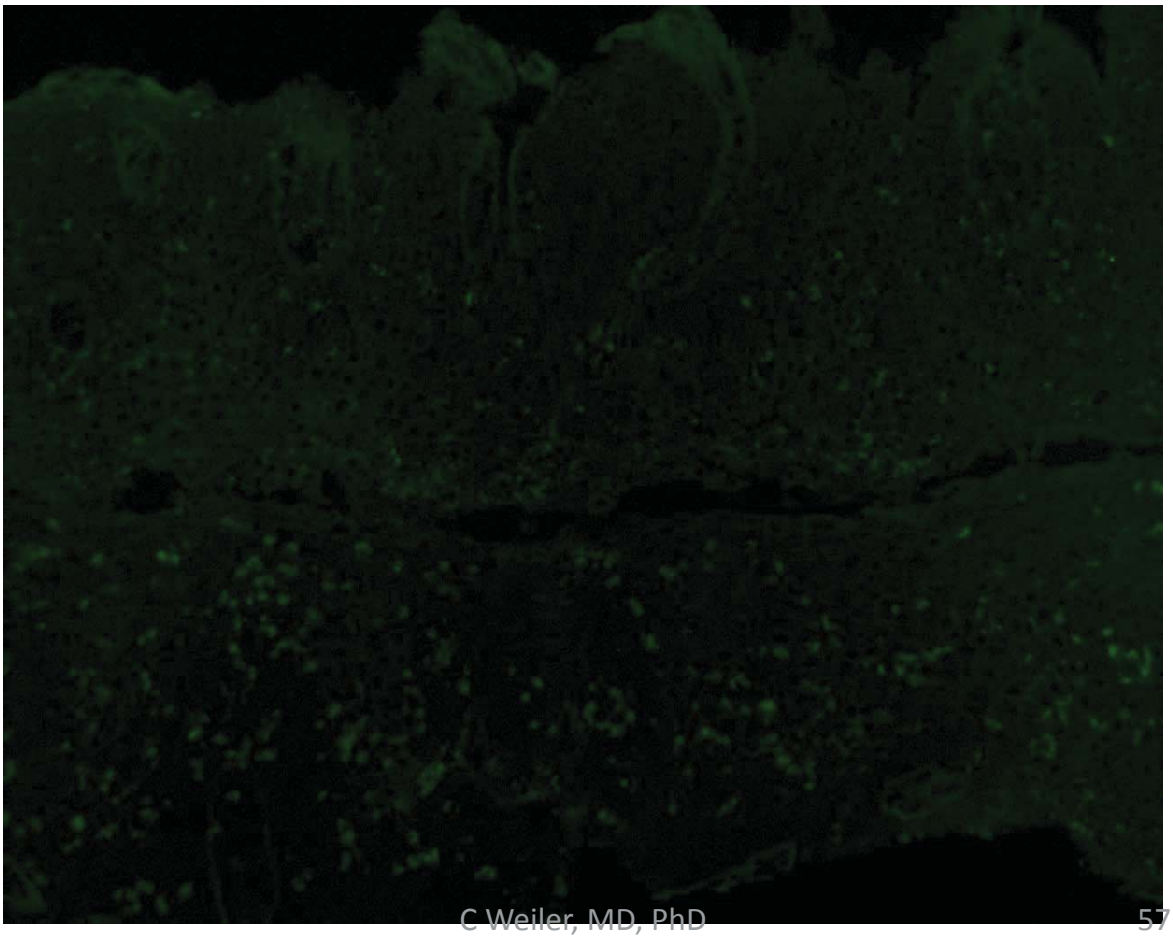

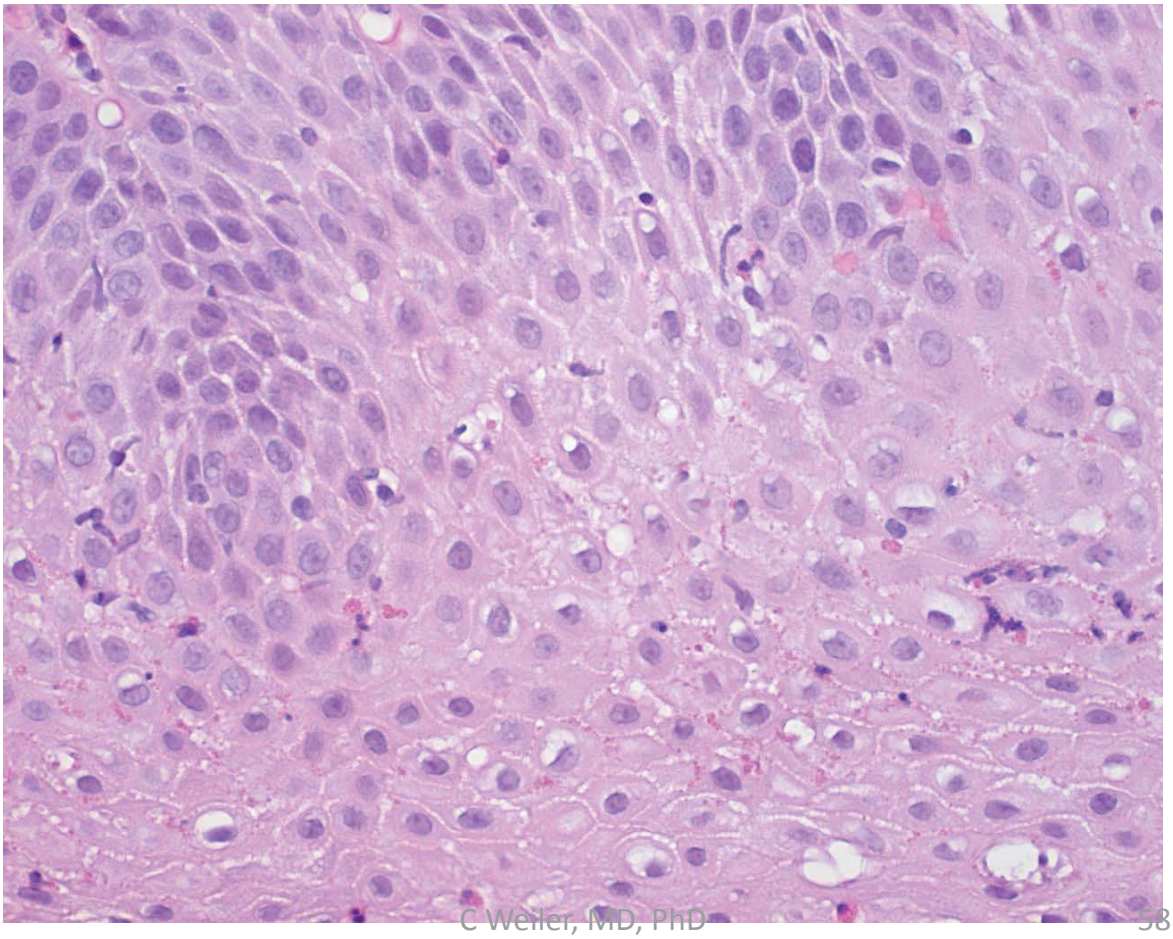

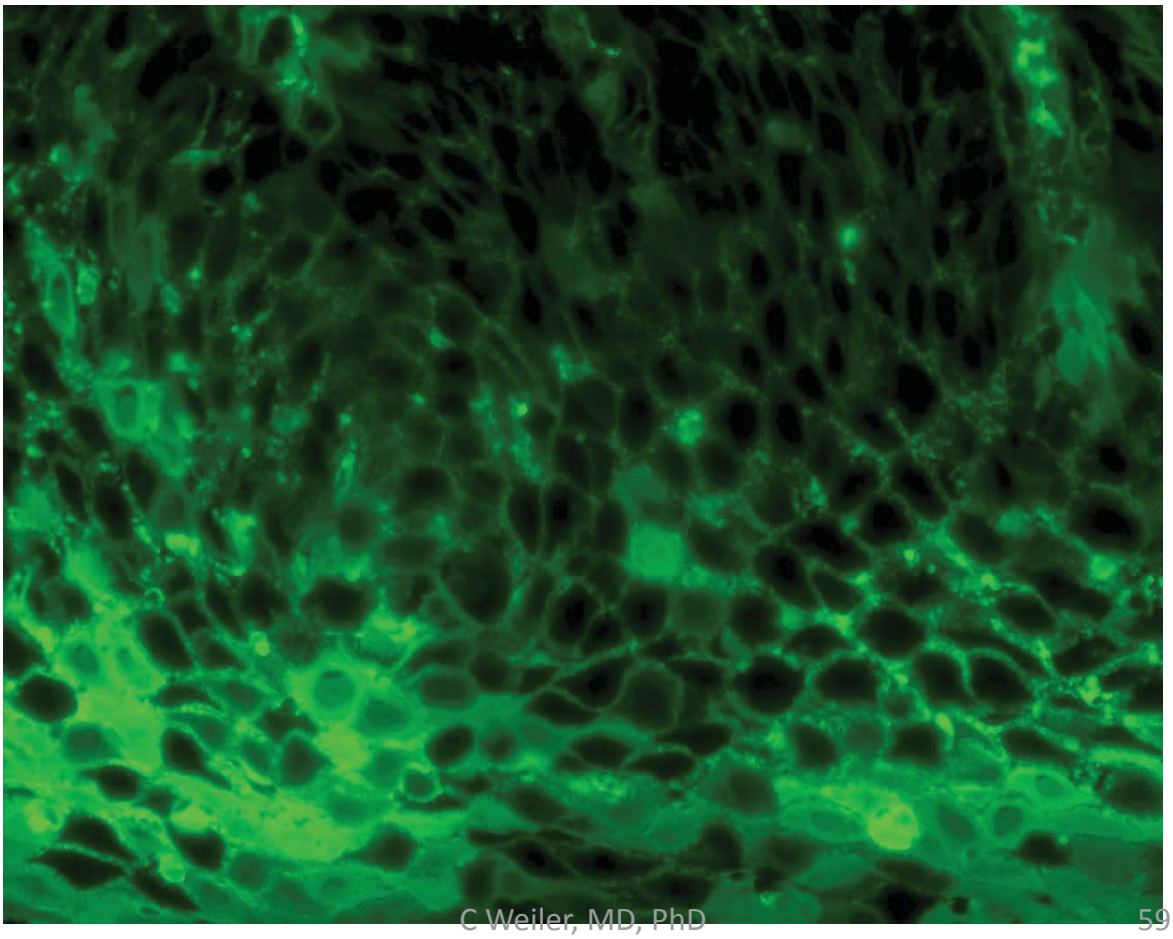



Weiler.Catherine@mayo.edu
(507) 284-3783

THANK YOU

EoE articles of interest

- *Allergy Asthma Proc. 2017 May 1;38(3):170-176*. **Medical therapy versus dietary avoidance in eosinophilic esophagitis: Which approach is better?** Chehade M, Sher E.
- *Am J Gastroenterol. 2017 Apr 18 doi: 10.1038/ajg.2017.107. [Epub ahead of print]* **Esophageal and Small Intestinal Mucosal Integrity in Eosinophilic Esophagitis and Response to an Elemental Diet** Warners MJ et. al.

EoE Articles of Interest

- *J Clin Invest 20 Jan 2012; 107(1):83-90* **An etiological role for aeroallergens and eosinophils in experimental esophagitis**. Mishra A, et. al.
- *Annu Rev Pathol.* *2016 May 23;11:365-93*. **Mechanisms of Disease of Eosinophilic Esophagitis.** Davis BP, Rothenberg ME
- *Dis Esophagus.* *2017 Feb 1;30(3):1-8* **Newly developed and validated eosinophilic esophagitis histology scoring system and evidence that it outperforms peak eosinophil count for disease diagnosis and monitoring.** Collins MH[1], et.al.

EoE articles of interest

- *Am J Gastroenterol.* *2015 Sep;110(9):1347-54*. **A Clinical Prediction Tool Identifies Cases of Eosinophilic Esophagitis Without Endoscopic Biopsy: A Prospective Study.** Dellon ES[1,2], et. al.
- *J Allergy Clin Immunol.* *2011 Jul;128(1):3-20.e6* **Eosinophilic esophagitis: updated consensus recommendations for children and adults.** Liacouras C, et.al.
- *Gastroenterology, October 2007. 133(4):1342–1363* **Eosinophilic Esophagitis in Children and Adults: A Systematic Review and Consensus Recommendations for Diagnosis and Treatment: Sponsored by the American Gastroenterological Association (AGA) Institute and North American Society of Pediatric Gastroenterology, Hepatology, and Nutrition** G.T. Furuta, , et al.
- *J Allergy Clin Immunol. 2001 Dec;108(6):891-4* **Pathogenesis and clinical features of eosinophilic esophagitis.** Rothenberg ME, et.al.

Towards Molecular Definition of EoE

- **Eosinophilic esophagitis-linked calpain 14 is an IL-13-induced protease that mediates esophageal epithelial barrier impairment.** Davis BP[1], Stucke EM[1], Khorki ME[1], Litosh VA[1], Rymer JK[1], Rochman M[1], Travers J[1], Kottyan LC[2], Rothenberg ME[1] JCI Insight. 2016 Apr;1(4):e86355.
- **Eosinophilic esophagitis phenotypes: Ready for prime time?** Dan Atkins, Glenn T. Furuta, Chris A. Liacouras & Jonathan M. Spergel. Pediatr Allergy Immunol. 2017 Jun;28(4):312-319.