Dermatologic Manifestations of Primary Immunodeficiency

PAAA Annual Meeting
June 25, 2016

Edward W. Cowen, MD, MHSc
Senior Clinician and Head, Dermatology Consultation Service
Dermatology Branch, Center for Cancer Research
National Cancer Institute, National Institutes of Health

Speaker Disclosure

"No relevant financial relationships with commercial interests"

Dermatologic Manifestations of Primary Immunodeficiencies

Powerful genetic techniques

Precise phenotyping

- 2014 International Union of Immunological Societies Expert Committee for Primary Immunodeficiency
  - 250 PIDs
  - 30 new genes since 2011 report (1 disease/5 wks)

Front Immunol. 2014 Apr 22;5:162.

Primary immunodeficiency: dermatology perspective

PID skin manifestations

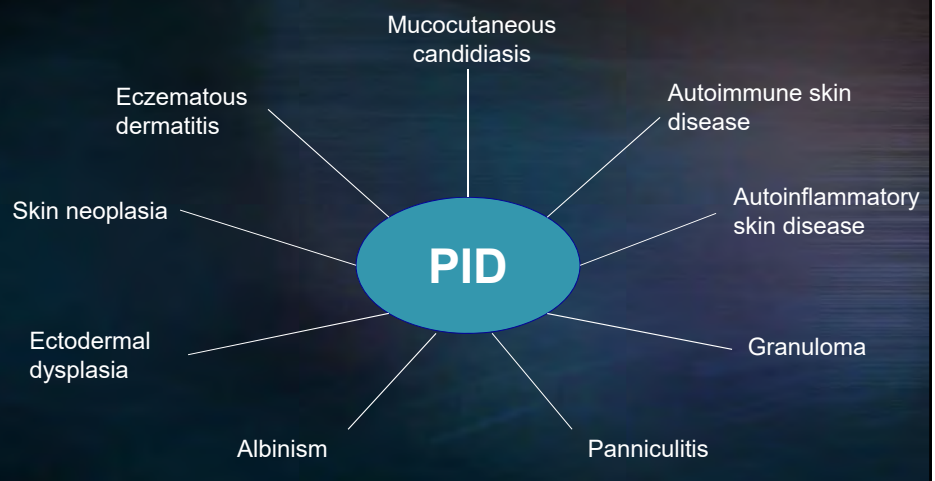

PID skin manifestations

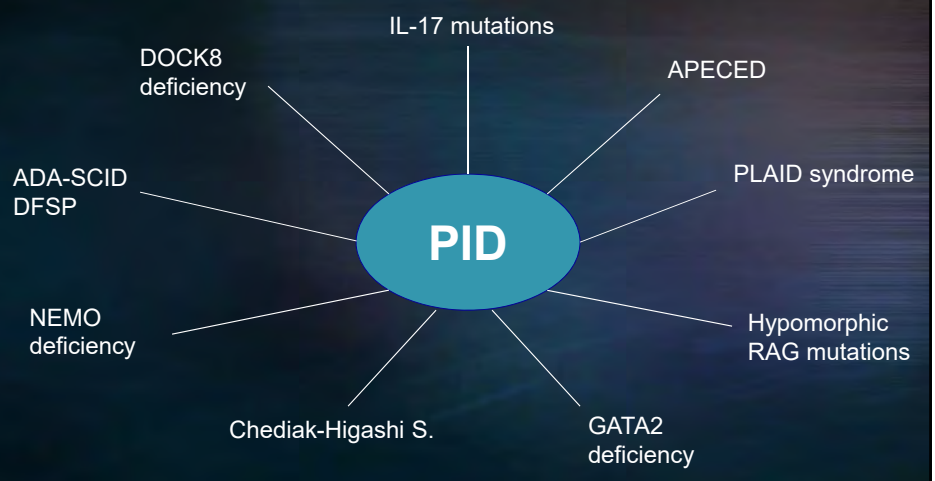

Primary immunodeficiency

- Common things are common, even in the immunocompromised setting

T. Corporis HIV

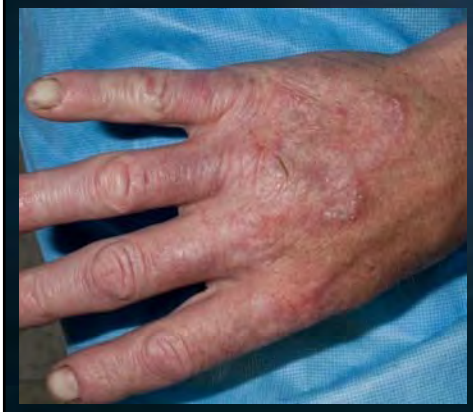

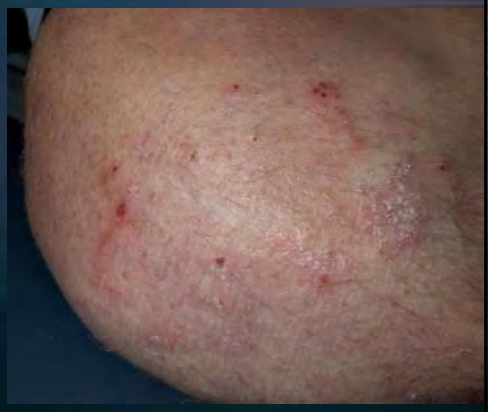

Primary immunodeficiency

- Common things are common, even in the immunocompromised setting
- Common things present in an uncommon manner in the immunocompromised setting

Idiopathic CD4 lymphocytopenia : condyloma

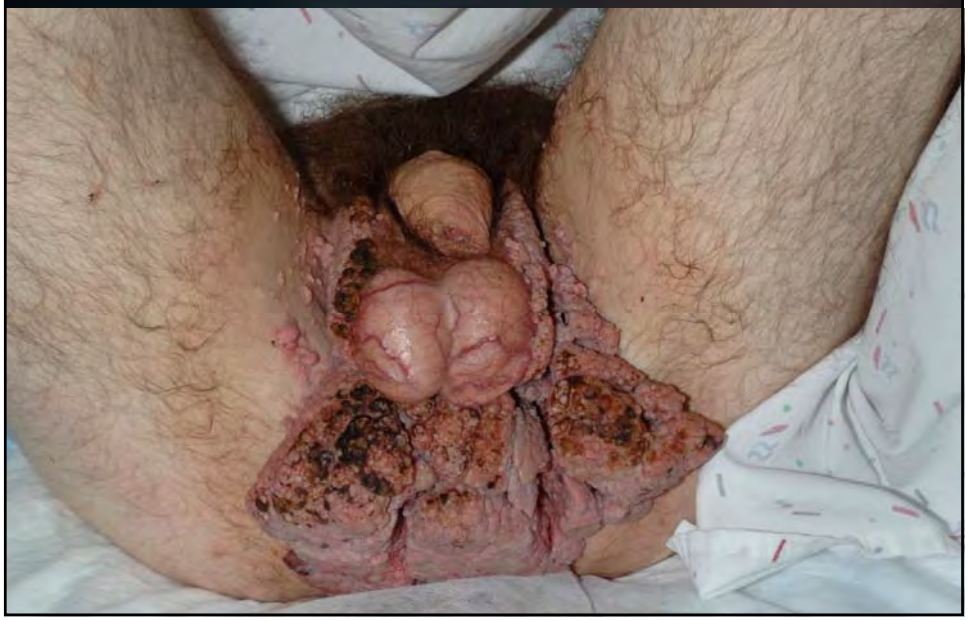

Molluscum contagosium: DOCK8 combined immunodeficiency

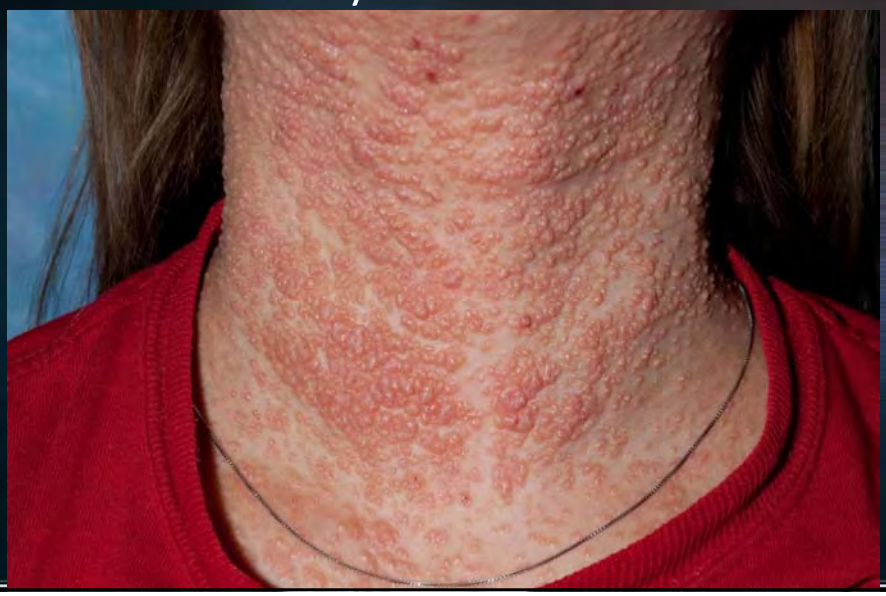

Primary immunodeficiency

- Common things are common, even in the immunocompromised setting
- Common things present in an uncommon manner in the immunocompromised setting
- Uncommon things occur in the immunocompromised setting

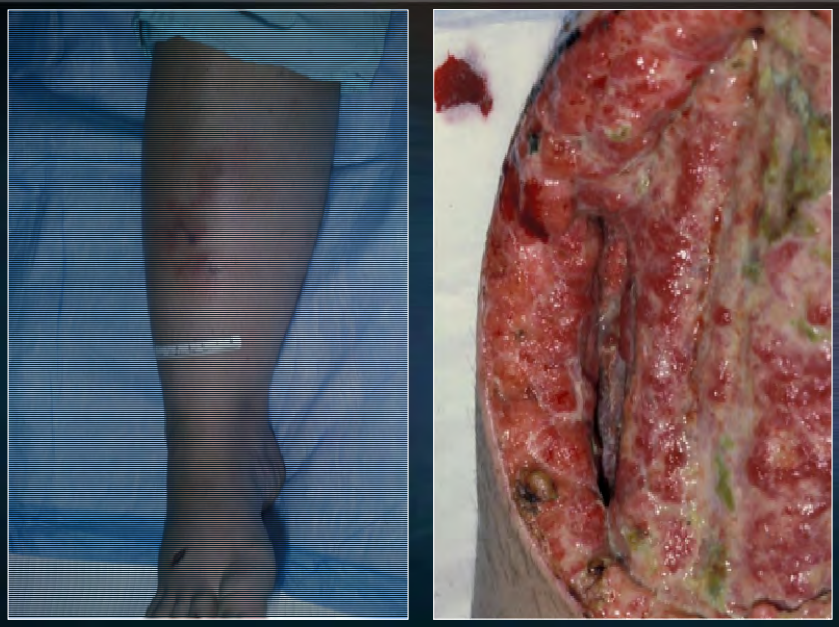

Hyper-IgE S.: Group A β-hemolytic *Strept.* necrotizing fasciitis

38 y.o. SLE pt. on prednisone 50mg QD, anakinra

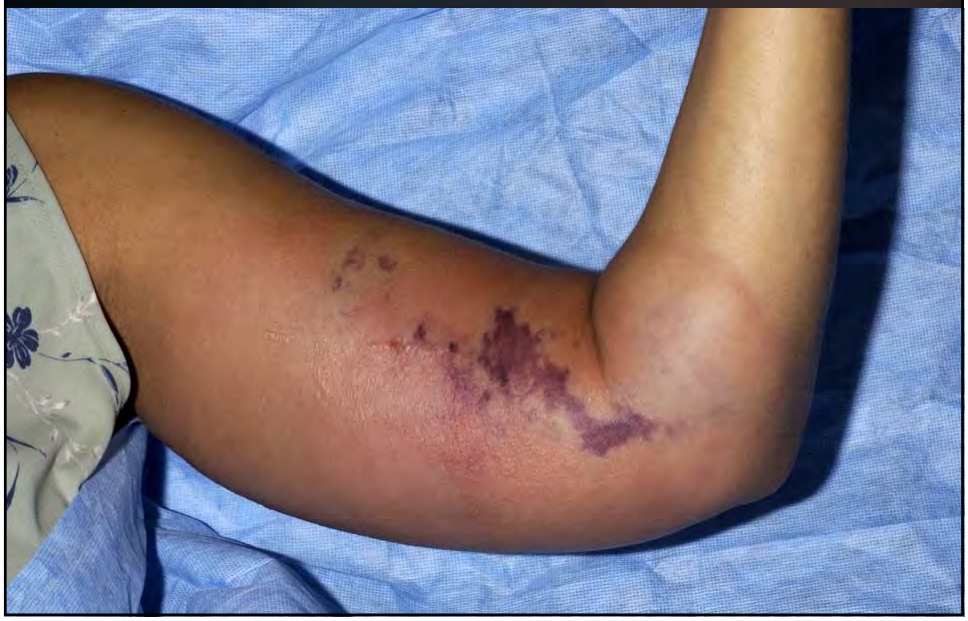

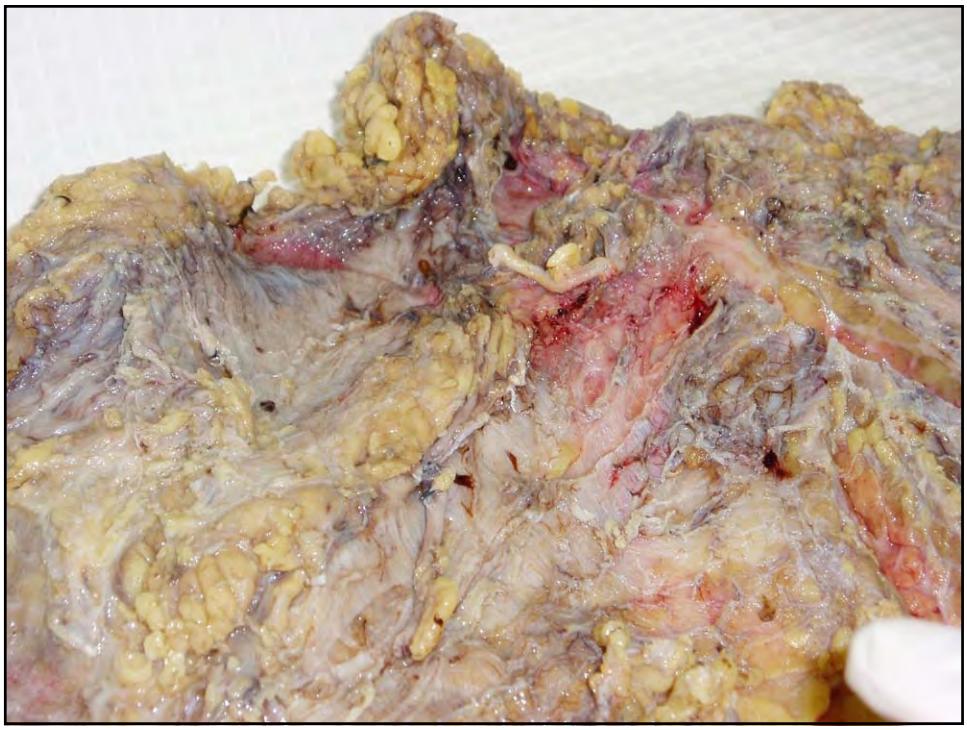

Serratia marcescens necrotizing fasciitis

Necrotizing fasciitis caused by Serratia marcescens in two patients receiving corticosteroid therapy.
Huang JW, Fang CT, Hung KY, Hsueh PR, Chang SC, Tsai TJ.

J Formos Med Assoc. 1999 Dec;98(12):851-4.

- Hemorrhagic bullae
- Bluish skin discoloration
- Severe pain vs. anesthesia

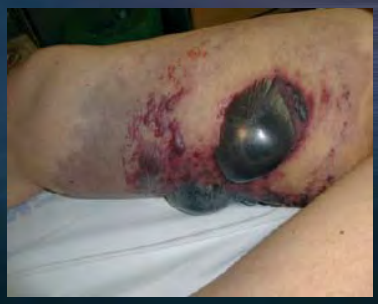

Fulminant NF caused by *S.marcescens* in an immunosuppressed host.
Int J Dermatol May 29, 2012.

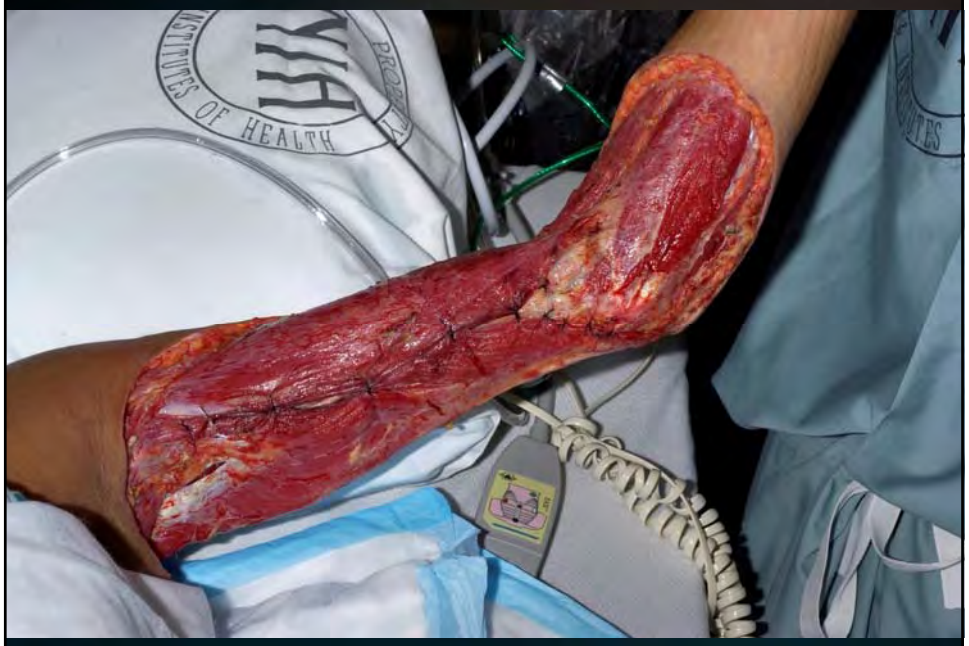

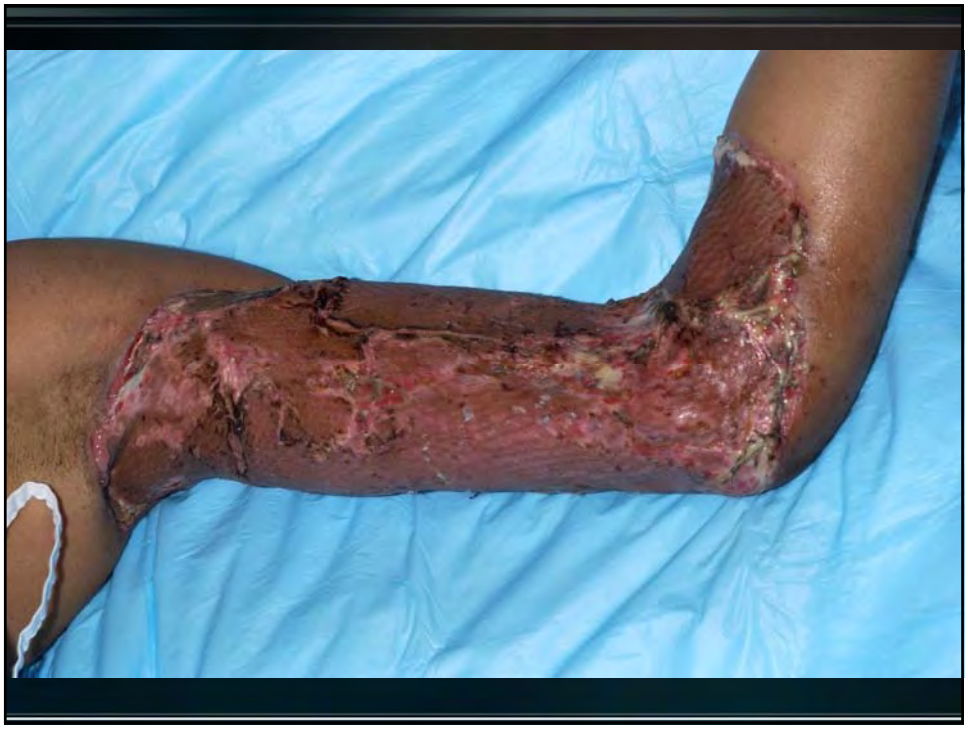

X-linked (Bruton) agammaglobulinemia

- 17 y.o. male: 4 mo. hx leg ulceration
  - Blood culture: negative
  - Tissue culture: thin film (non-cultivable) surrounding Group B Strept. colony
- Histology: suppurative granuloma
  - PAS, Fite, Brown & Bren, GMS negative
  - Warthin-Starry: curvilinear, rod-like organisms

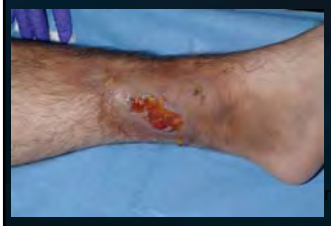
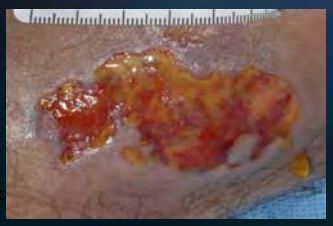
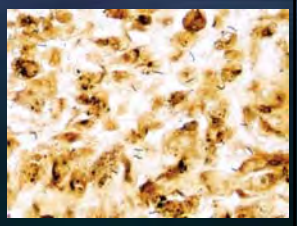

- Bacteremia and skin/bone infections in two patients with X-linked agammaglobulinemia caused by…*Flexispira/Helicobacter species. Clin Immunol. 2000;97(2):121-129.*

- Mass Spectrometry for ID of human infection (IBIS Bioscience)
  - Amplification of species-specific 16s rDNA sequences
  - Mass of the amplified products by mass spectrometer

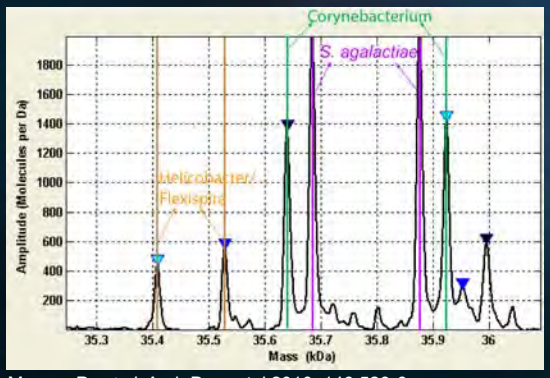

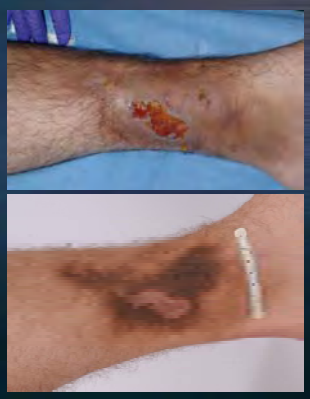

Murray P. *et al.* Arch Dermatol 2010; 146:523-6.

XLA *H. bilis* masquerading as morphea/ eosinophilic fasciitis

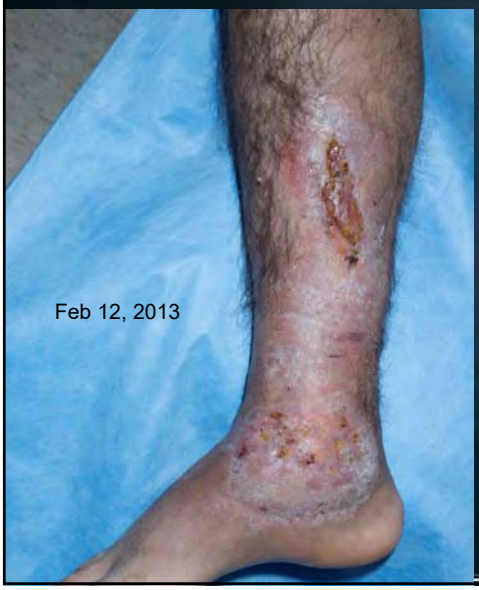

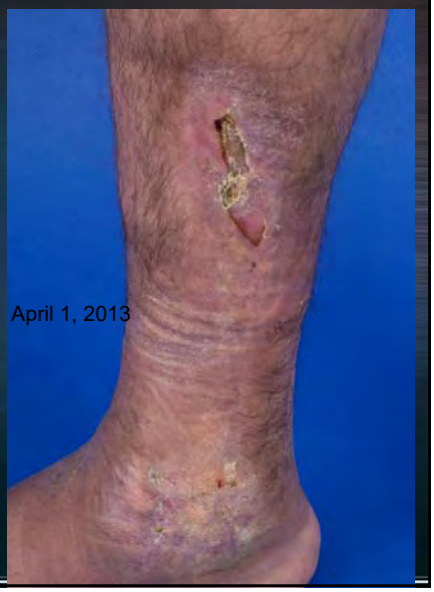

Primary ID: dermatology perspective

- Common things are common, even in the immunocompromised setting
- Common things present in an uncommon manner in the immunocompromised setting
- Uncommon things occur in the immunocompromised setting
- Not every skin manifestation in the immunocompromised setting is an infection

Common variable immunodeficiency

- Chronic chest pain/nausea
- Applied heating pad QD x >8 mo.
- Erythema ab igne

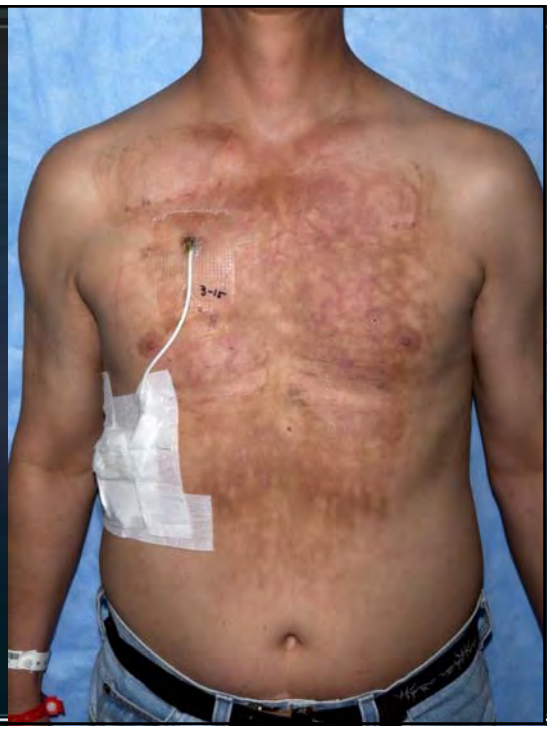

Erythema ab igne: 'physician branding'

Academic branding: erythema ab igne and use of laptop computers

David Botten MD, Richard G.B. Langley MD, Amanda Webb BSc

See related clinical image by Beleznay and colleagues, available at www.cmaj.ca

CMAJ. 2010 Dec 14;182(18):E857.

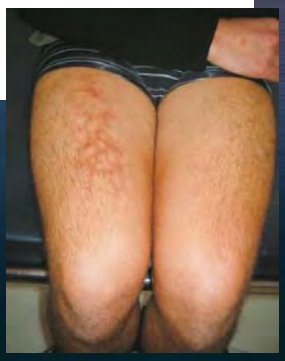

Non-infectious manifestations of primary immunodeficiency

Chronic granulomatous disease: lupus

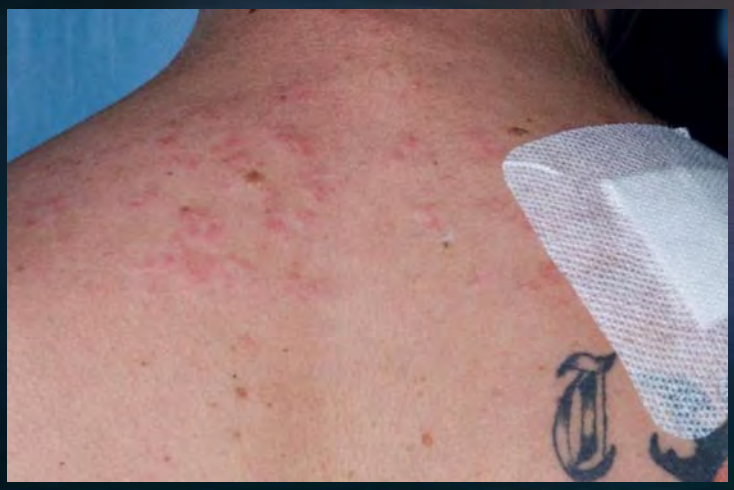

Chronic granulomatous disease as a risk factor for autoimmune disease

Suk See De Ravin, MD, PhD,[a] Nora Naumann, MD,[a] Edward W. Cowen, MD, MHSc,[c] Julia Friend, MPH, PA-C,[a] Dianne Hilligoss, RN, MSN, CRNP,[a] Martha Marquesen, NP,[a] James E. Balow, MD,[b] Karyl S. Barron, MD,[a] Maria L. Turner, MD,[c] John I. Gallin, MD,[a] and Harry L. Malech, MD[a] *Bethesda, Md*

Chronic granulomatous disease (CGD) is characterized by recurrent infections and granuloma formation. In addition, we have observed a number of diverse autoimmune conditions in our CGD population, suggesting that patients with CGD are at an elevated risk for development of autoimmune disorders. In this report, we describe antiphospholipid syndrome, recurrent pericardial effusion, juvenile idiopathic arthritis, IgA nephropathy, cutaneous lupus erythematosus, and autoimmune pulmonary disease in the setting of CGD. The presence and type of autoimmune disease have important treatment implications for patients with CGD. (J Allergy Clin Immunol 2008;122:1097-103.)

Abbreviations used

ANA: Antinuclear antibody
aPL: Antiphospholipid syndrome
CGD: Chronic granulomatous disease
CT: Computed tomography
JIA: Juvenile idiopathic arthritis
LE: Lupus erythematosus
NIH: National Institutes of Health
PID: Primary immunodeficiency
RF: Rheumatoid factor

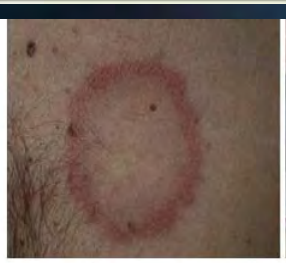

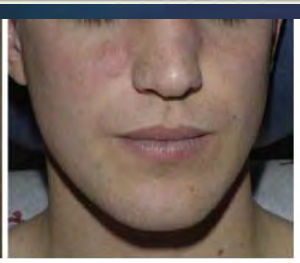

Chronic granulomatous disease: lupus

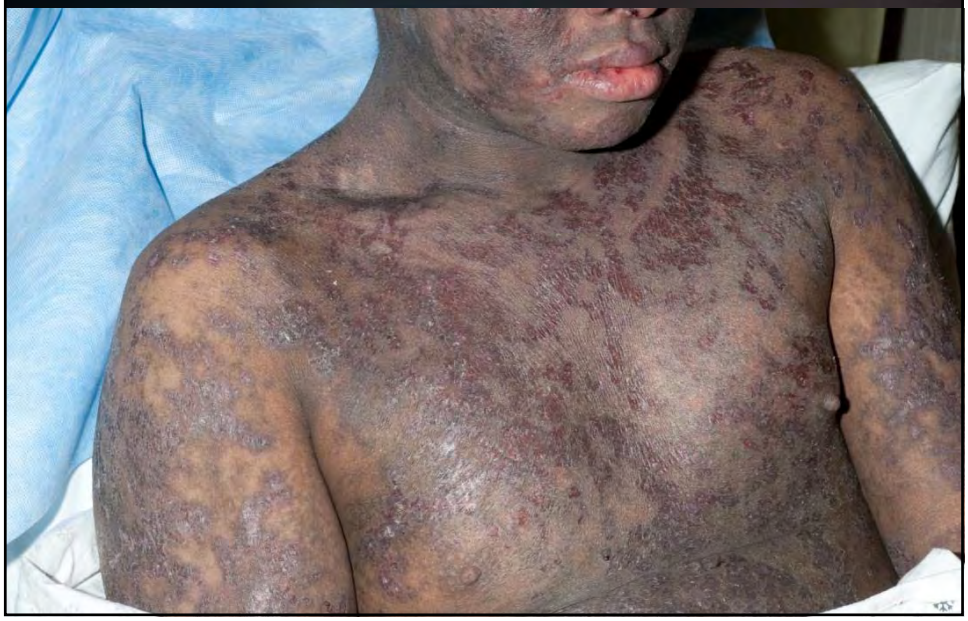

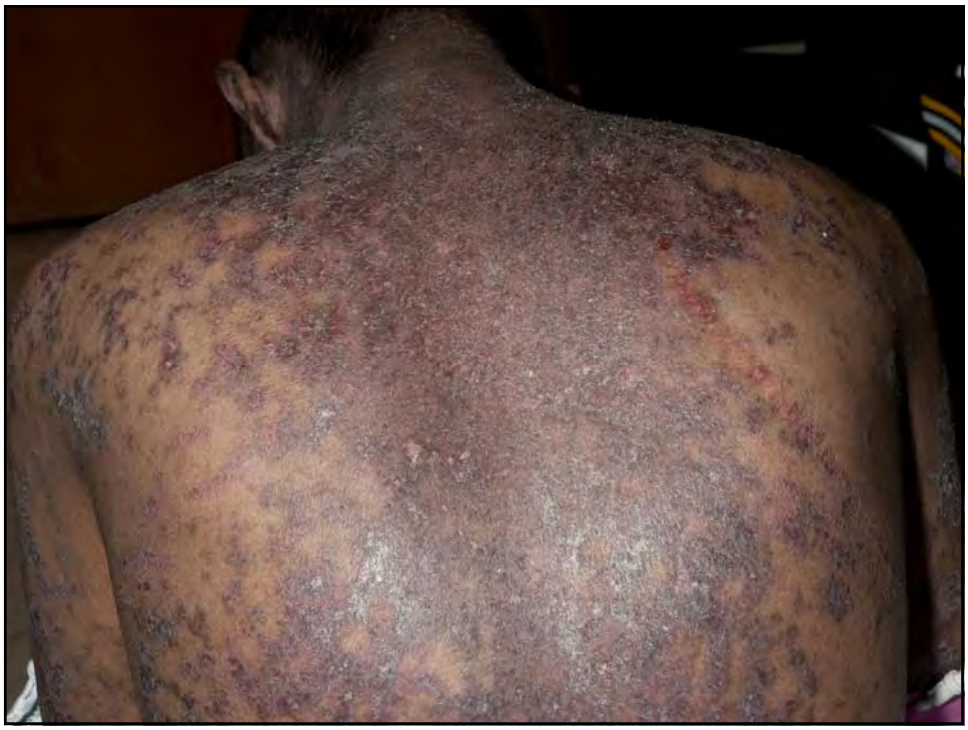

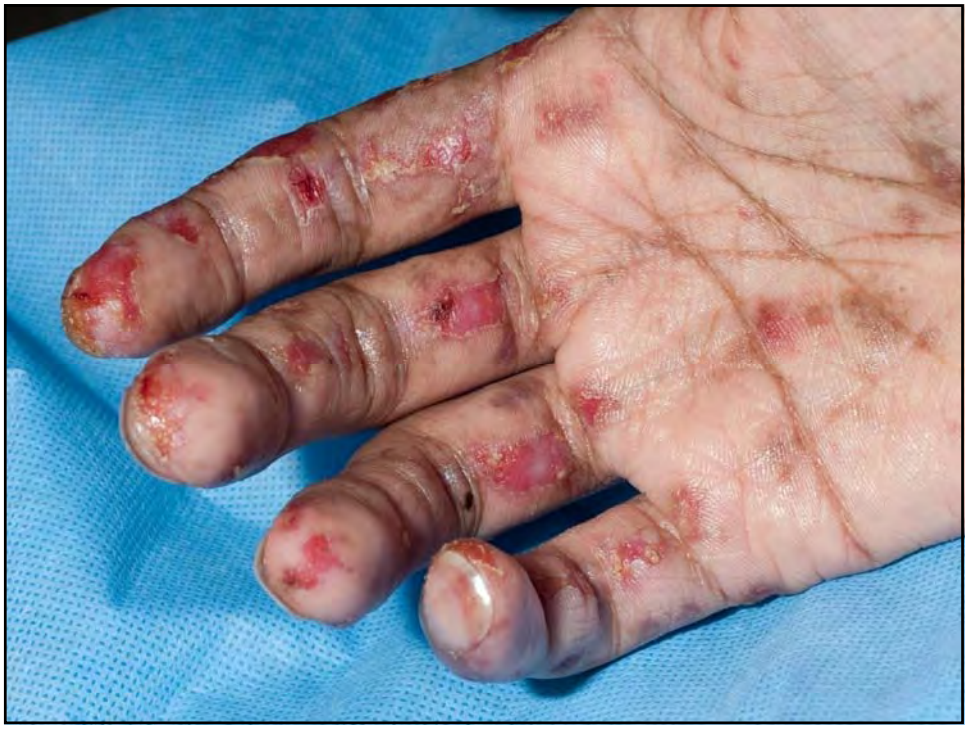

Autoimmunity and immunodeficiency

- Chronic granulomatous disease
  - Cutaneous lupus
- X-linked agammaglobulinemia
  - Dermatomyositis, RA
- Wiskott-Aldrich S.
  - Colitis, AIHA, glomerulonephritis
- CVID
  - Autoimmunity, granuloma

Autoimmunity, granuloma, and immunodeficiency

- Common variable immunodeficiency
  - Autoimmunity (23%)
  - Granuloma (8-20%)

Autoimmune conditions reported in patients with CVID

Idiopathic thrombocytopenia purpura	Nephrotic syndrome
Hemotytic anemia	Systemic lupus erythematosus
Rheumatoid arthritis	Vasculitis
Juvenile rheumatoid arthritis	Dermatomyositis
Sicca syndrome	Sjogren's syndrome
Primary biliary cirrhosis	Guillain–Barre
Alopecia	Hyperthyroidism
Pernicious anemia	Autoimmune neutropenia

Autoimmunity Rev 5 (2006) 156–159

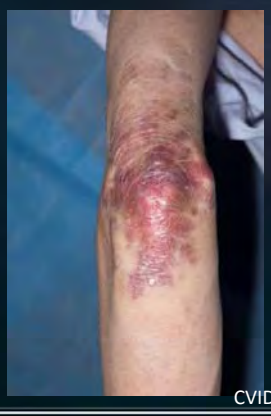

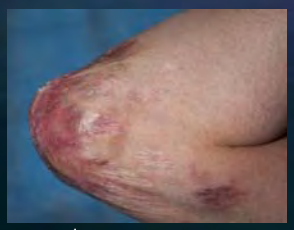

CVID cutaneous granuloma

The NEW ENGLAND JOURNAL of MEDICINE

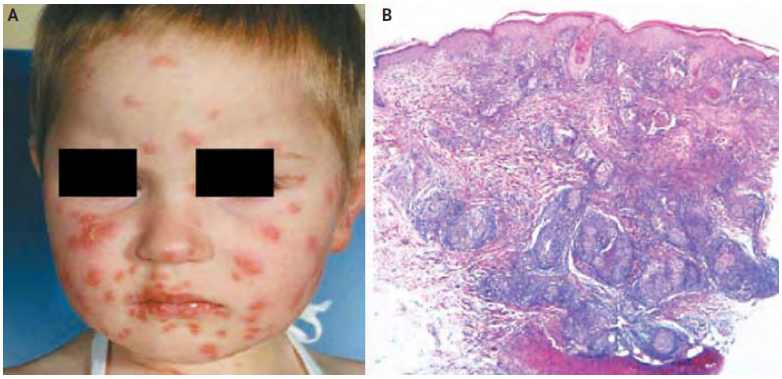

- 3 females (3, 7, 10 yrs)
  - 2/3 no significant infections prior to diagnosis
  - Cutaneous granulomas (CD8+)
  - Compound heterozygotes (RAG1, RAG2 mutations)

N Engl J Med 2008; 358:2030-2038

"Leaky" or "Atypical" SCID

- Hypomorphic Rag mutations
  - Residual recombination activity (5-30%)
  - $T^+ B^+ NK^+$ (low for age); Ig NL or low
  - Infection risk highly variable/late onset
- Granulomatous disease
  - Skin, lungs, tongue, adenoids, spleen
- Multiple autoimmune conditions
  - Autoimmune cytopenias

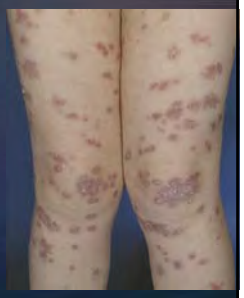

N Engl J Med 2008; 358:2030-2038

Blood 2010;116:1263-71.

Hypomorphic Rag mutations can cause destructive midline granulomatous disease

Suk See De Ravin,[1] Edward W. Cowen,[2] Kol A. Zarember,[1] Narda L. Whiting-Theobald,[1] Douglas B. Kuhns,[3] Netanya G. Sandler,[4] Daniel C. Douek,[4] Stefania Pittaluga,[5] Pietro L. Poliani,[6] Yu Nee Lee,[7] Luigi D. Notarangelo,[7] Lei Wang,[7] Frederick W. Alt,[7] Elizabeth M. Kang,[1] Joshua D. Milner,[1] Julie E. Niemela,[8] Mary Fontana-Penn,[9] Sara H. Sinal,[9] and Harry L. Malech[1]

[1]Laboratory of Host Defenses, National Institute of Allergy and Infectious Diseases and [2]Dermatology Branch, National Cancer Institute, National Institutes of Health (NIH), Bethesda, MD; [3]Clinical Services Program, SAIC-Frederick Inc, Frederick, MD; [4]Vaccine Research Center, [5]Pathology, National Cancer Institute, NIH, Bethesda, MD; [6]Department of Pathology, University of Brescia, Brescia, Italy; [7]Division of Immunology, Children's Hospital Boston, Harvard Medical School, Boston, MA; [8]Department of Laboratory Medicine, Clinical Center, NIH, Bethesda, MD; [9]Department of Pediatrics, Wake Forest University School of Medicine, Winston-Salem, NC

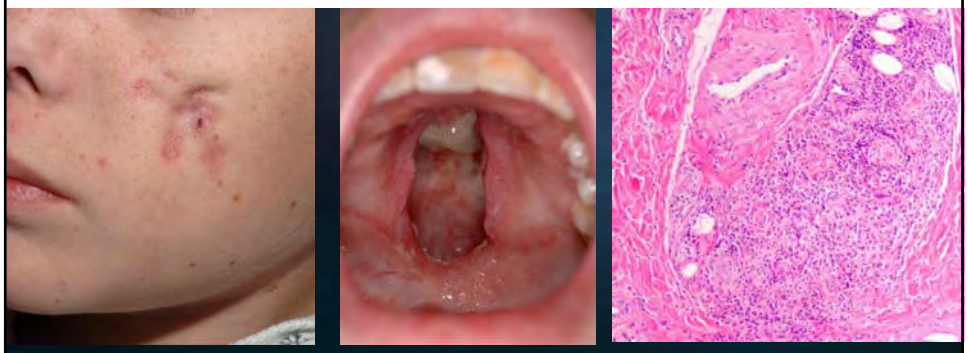

Compound heterozygote *Rag1*; normal TCR repertoire, myasthenia gravis

Spectrum of *Rag*-associated diseases

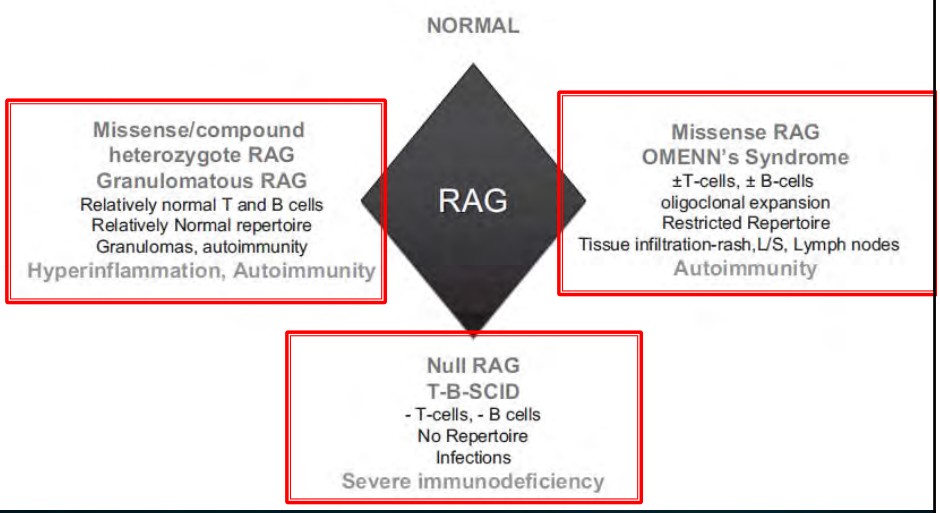

Blood 2010;116:1263-71.

Phospholipase $C\gamma_2$ Associated Disease

- Familial *atypical* cold urticaria
- Familial cold autoinflammatory syndrome 3 (FCAS3)
- 'PLAID'

OMIM 614468

Phospholipase Cγ2-associated Antibody deficiency and Immune Dysregulation (PLAID)

- Evaporative cold urticaria (27/27)
- Granulomatous rash
- Autoimmunity (thyroiditis, ANA)
- Sinopulmonary infection

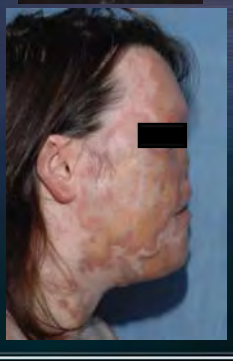

N Engl J Med 2012;366:330-8.

PLAID cold urticaria

- Symptoms within first year of life
- Flare > wheal
- Evaporative cooling, cold water immersion (swimming) → syncopal episodes
- Cold food ingestion → esophageal burning
- Antihistamines → limited benefit

PLAID/PLAID-like disease (n = 36)

Table. Cutaneous and Immunologic Features of Patients With PLAID and PLAID-Like Disease[a]

Patient No./Sex	*PLCG2* Deletion	Cold Urticaria	Condition	Autoimmunity	Infectious History	Neonatal Lesion Distribution	Time to Lesion Resolution	Cutaneous Granuloma
1/M	Yes	Yes	Food allergy (fish)	Seronegative inflammatory arthritis	Recurrent sinusitis and pneumonia, treated with IVIG	Nose, ears, toes, cheeks	NA[b]	Yes
2/M	Yes	Yes	Asthma, AR, food allergy (fish)	None	Recurrent pneumonia, bronchitis	Nose	NA[c]	Yes
3/F	Yes	Yes	AR, food allergy (shellfish and chocolate)	Positive ANA test result	Recurrent sinusitis	Nose	<1 y	Yes
4/F	Yes	Yes	None	Hashimoto thyroiditis, vitiligo, positive ANA test result	Recurrent pneumonia in childhood	Nose	6 mo	Yes
5/M	Yes	Yes	Asthma, eczema	Positive ANA test result	None	Nose, fingers, toes	2 wk	No
6/M	Yes	Yes	None	Positive ANA test result	None	Nose, fingers, toes	2 wk	No
7/M	Yes	Yes	Asthma	Vitiligo, positive ANA test result	None	Nose	1 wk	No
8[d]/M	No	Yes	None	None	Recurrent sinopulmonary infections, treated with IVIG	Nose, fingers, toes	6 wk	No

JAMA Dermatol. ePub March 11, 2015.

PLAID nasal ulceration

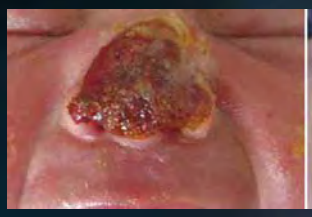

Day 3 of life

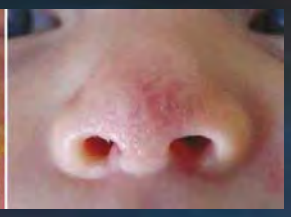

6 weeks

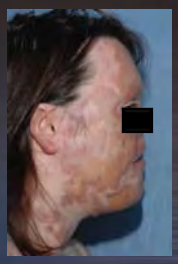

Nasal destruction

- Resolution 1 wk → 1 year (6/8)
- Histopathology/pathogenesis?
- Vesicles/erosions fingers/toes
  - Temperature-related?

JAMA Dermatol. ePub March 11, 2015.

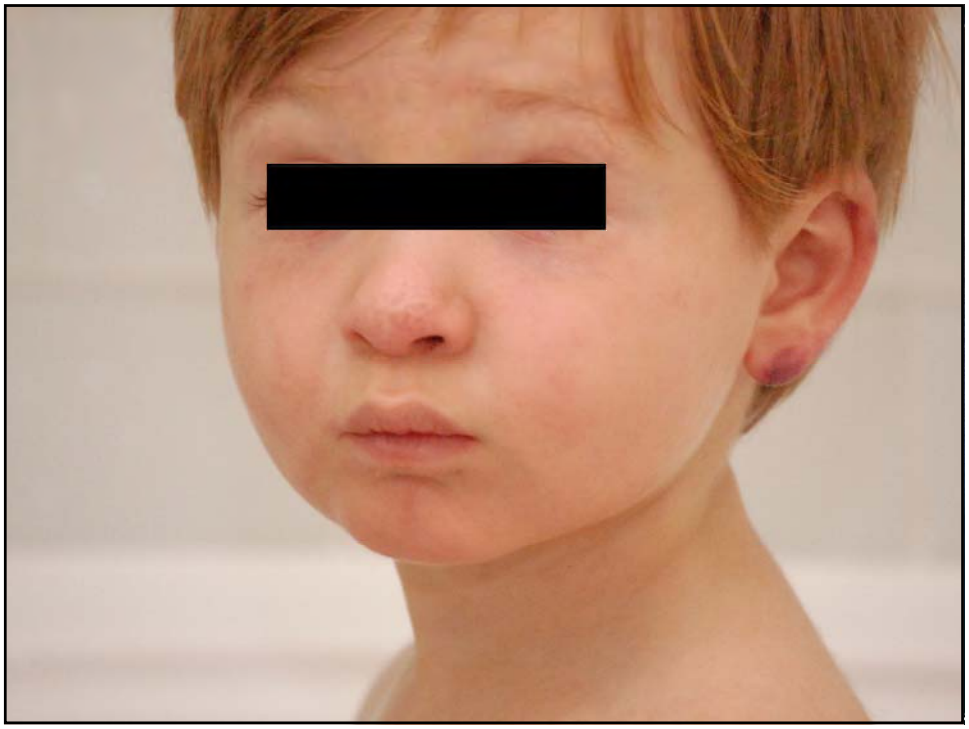

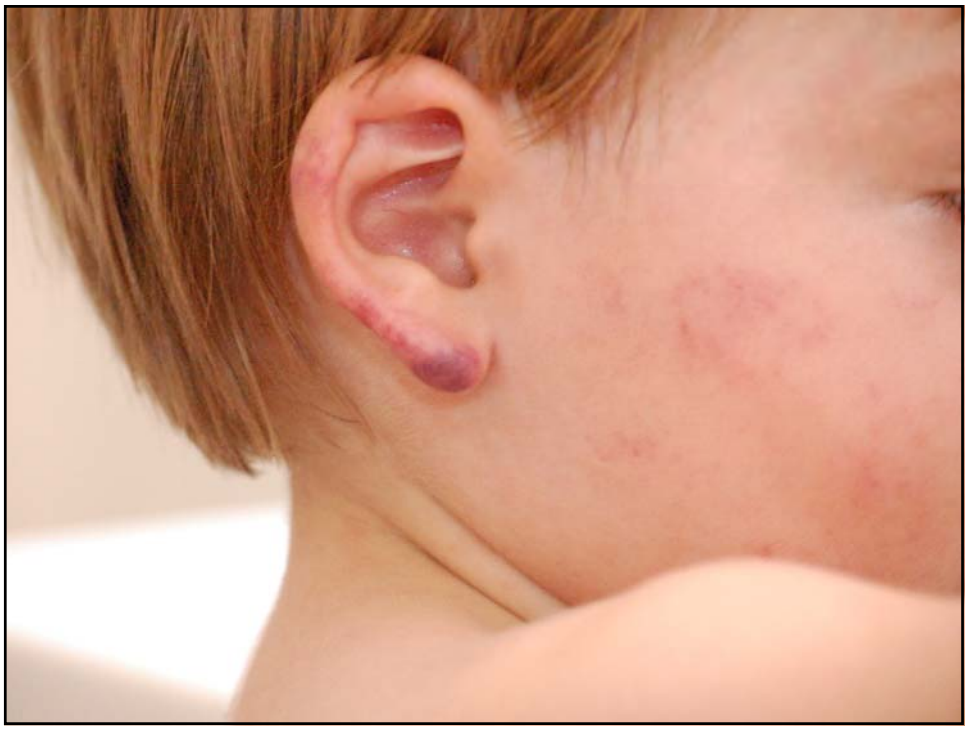

PLAID granulomatous skin disease

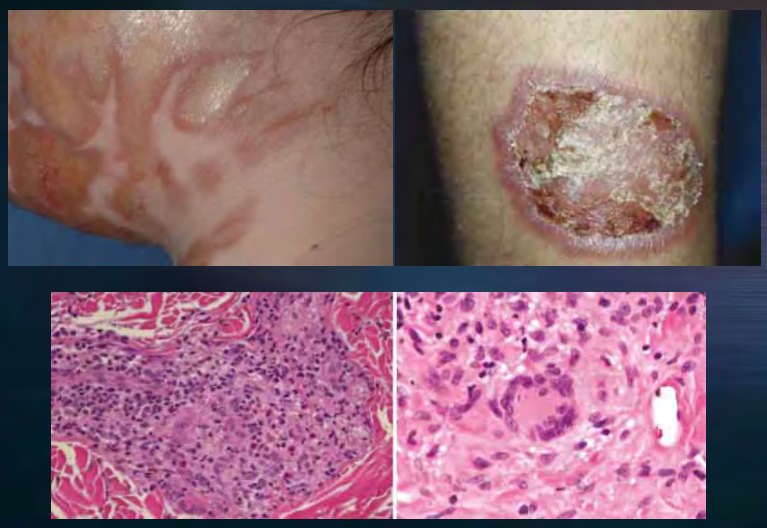

JAMA Dermatol. ePub March 11, 2015.

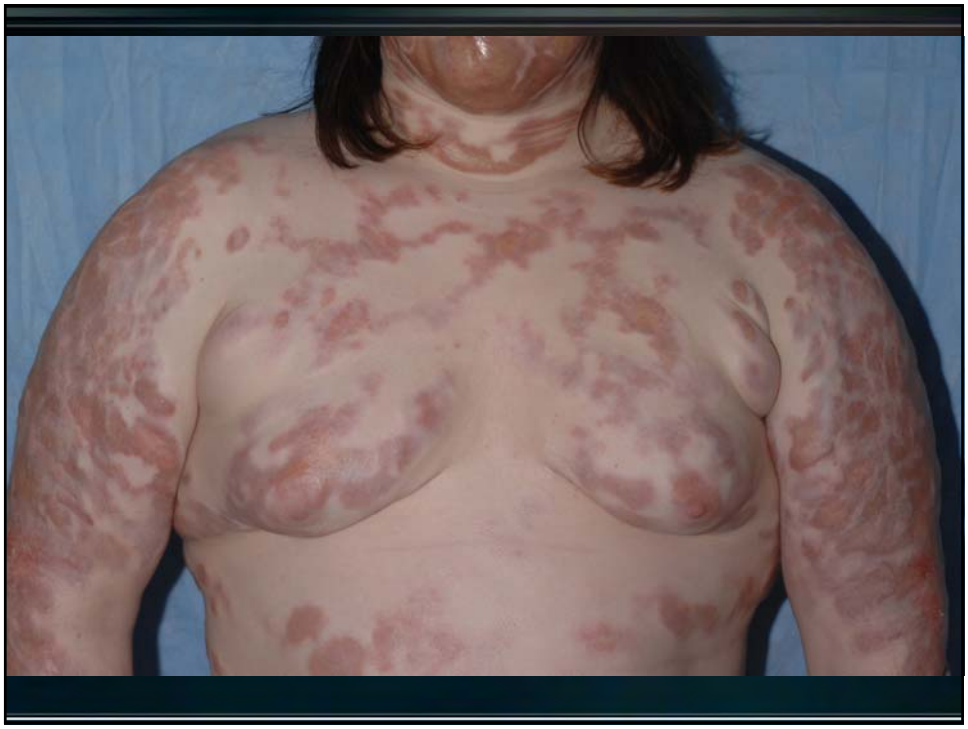

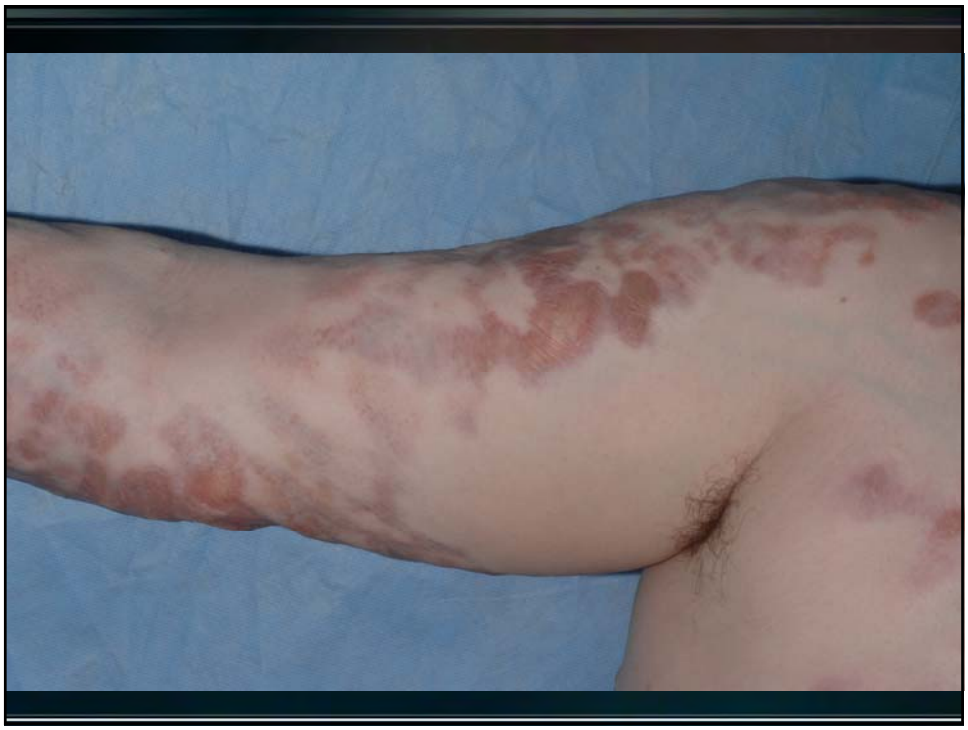

PLAID: Genomic deletion *PLCG2* inhibitory domain
Physiologic temp → ↓ activity (B, NK cells)
Cold temp → ↑ activity (mast cells)

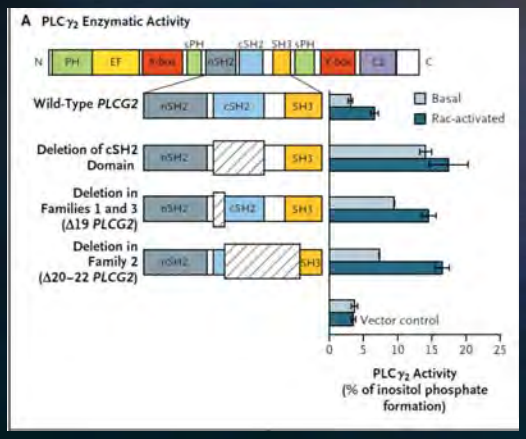

N Engl J Med 2012;366:330-8.

PLAID temperature-sensitivity

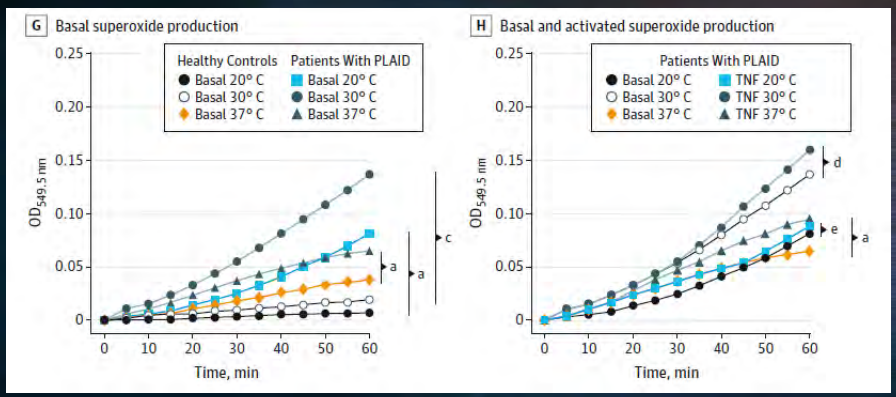

JAMA Dermatol. ePub March 11, 2015.

Implications

- Consider PLAID in patients with cold urticaria
  - Family Hx cold urticaria
  - Recurrent sinopulmonary infections
  - Neonatal nasal/acral ulceration
  - Granulomatous skin disease

Case 1

- 8 year-old recalcitrant dermatitis (bx-proven)

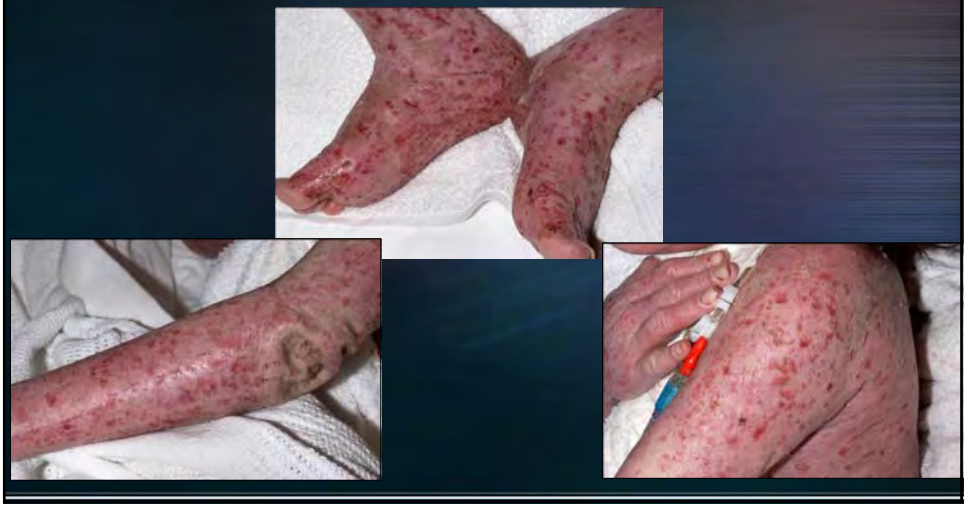

Case 1

- Diagnosis?
  - History
    - Infections: pneumonia, bacteremia, line infections

Case 1

- Diagnosis?
  - History
    - Infections: pneumonia, bacteremia, line infections

    - Family hx: two brothers, no parents

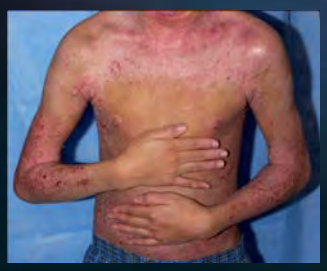

Case 1

- Diagnosis?
  - History
    - Infections: pneumonia, bacteremia, line infections
    - Family hx: two brothers, no parents
    - Atopic: anaphylaxis: cefipime; food allergy
    - M-Skeletal: no retained teeth, pathologic fx, or scoliosis

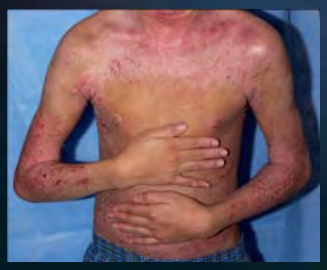

Case 1

- Physical evaluation
  - Oral exam: teeth, palate, tongue WNL
  - No hyperextensibility
  - Genitalia/skin folds
    - Bacterial, viral cultures: MRSA, HSV
- Skin biopsy: dermatitis
- Laboratory evaluation:
  - Eos: 1.472 (0-0.77k/ul); 22%
  - IgE: 14,500 (0-90 IU/ml)
- Severe atopic with MRSA, eczema herpeticum….or something more?

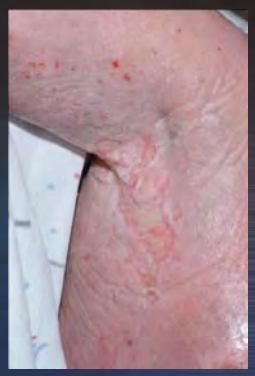

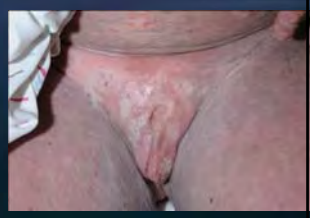

The NEW ENGLAND JOURNAL of MEDICINE
2009;361:2046-55.

ORIGINAL ARTICLE

Combined Immunodeficiency Associated with *DOCK8* Mutations

Qian Zhang, M.D., Jeremiah C. Davis, M.P.H., Ian T. Lamborn, B.S., Alexandra F. Freeman, M.D., Huie Jing, Ph.D., Amanda J. Favreau, B.S., Helen F. Matthews, B.S.N., Joie Davis, M.S.N., Maria L. Turner, M.D., Gulbu Uzel, M.D., Steven M. Holland, M.D., and Helen C. Su, M.D., Ph.D.

- Typical STAT3 HIES features:
  - Recurrent sinopulmonary infections
  - Recurrent *Staphlococcus aureus* skin infections
  - Elevated serum IgE
  - Severe chronic dermatitis
- Atypical features:
  - Lymphopenia
  - Asthma, severe food allergies/anaphylaxis
  - Severe cutaneous viral infections
  - Vulvar, facial, anal SCC, lymphoma

Dedicator of cytokinesis (DOCK8) immunodeficiency

- Autosomal recessive
- DOCK8
  - Regulate cytoskeletal rearrangements
  - Cell migration, polarization, fusion, phagocytosis
  - Activate Rho GTPases (Cdc42)

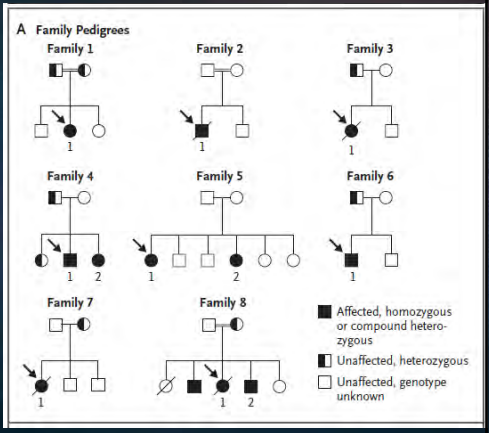

Su HC. Curr Opin Allergy Clin Immunol 2010;10:515–20.
Zhang et al. NEJM 2009;361:2046-55.

DOCK8 immunodeficiency: impetigo

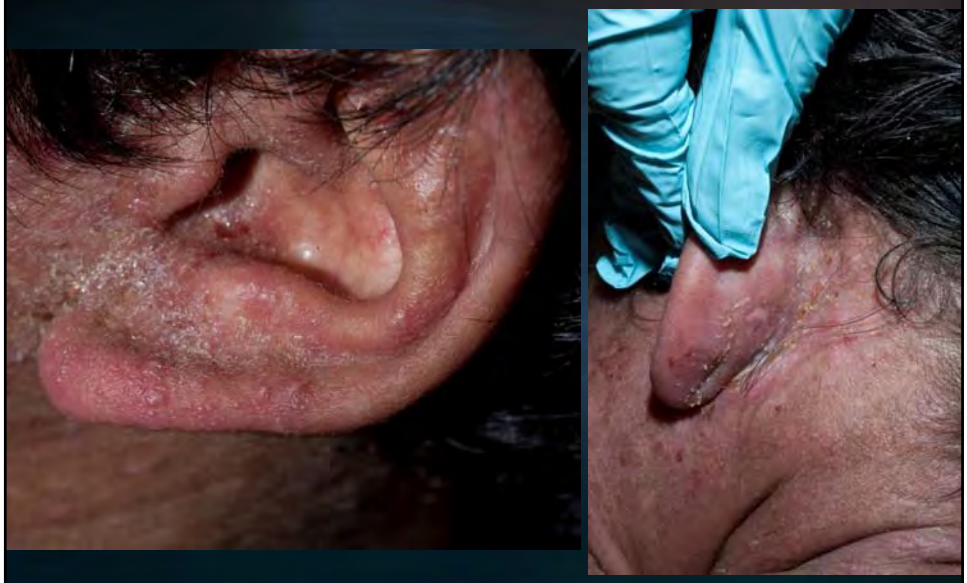

DOCK8 immunodeficiency: dermatitis

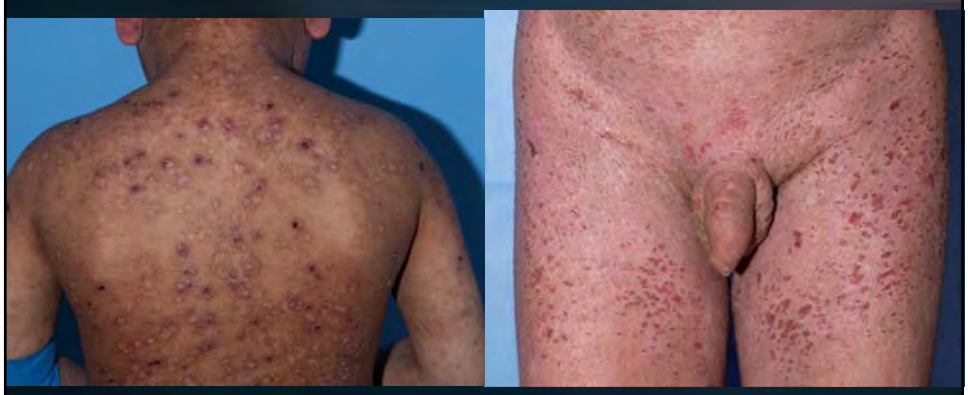

DOCK8 immunodeficiency: cutaneous features

Clinical or laboratory feature	Patients affected (%)
Atopic dermatitis	91
Asthma	41
Allergies	63
Bacterial skin infections	78
Mucocutaneous candidiasis	72
Any viral infection	88
HSV	47
HPV	28
MCV	41
VZV	22

Su HC. Curr Opin Allergy Clin Immunol 2010;10:515–520.

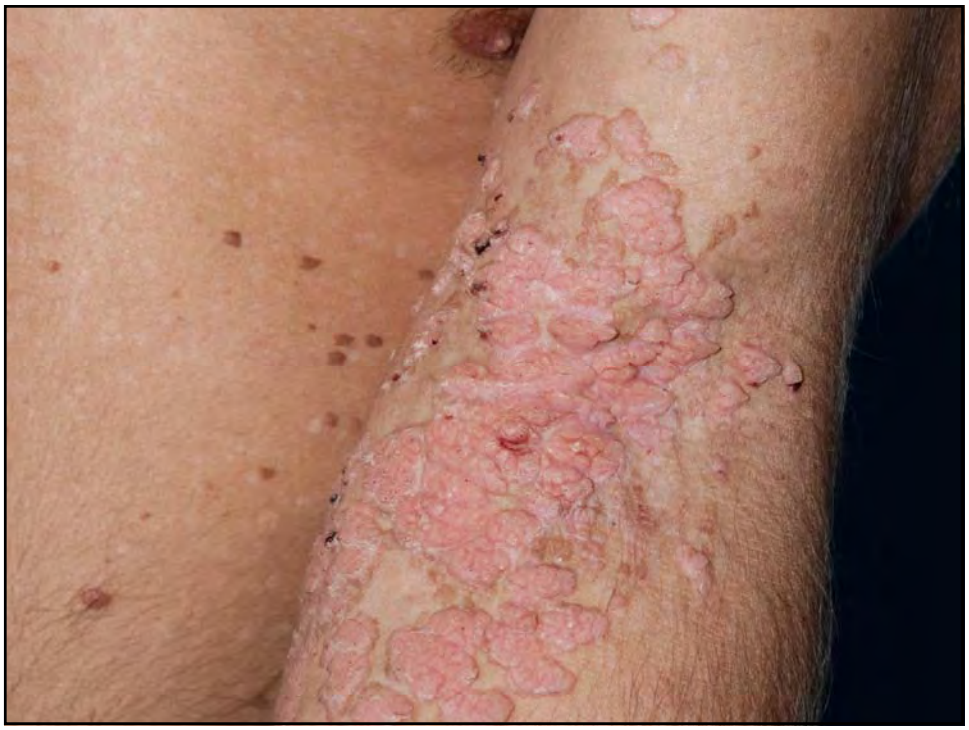

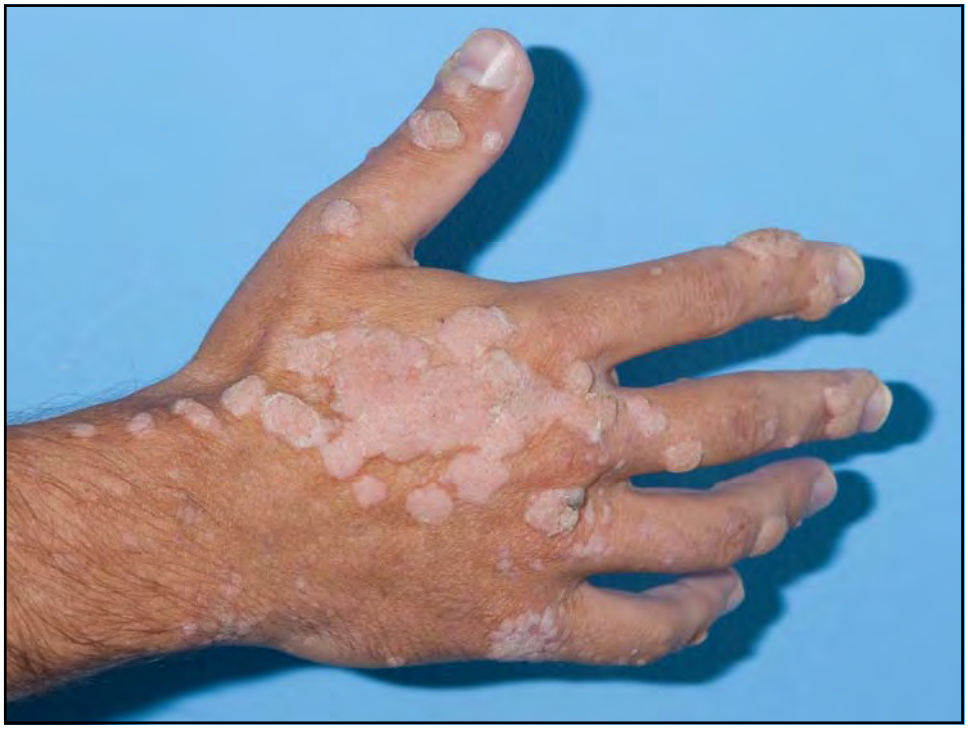

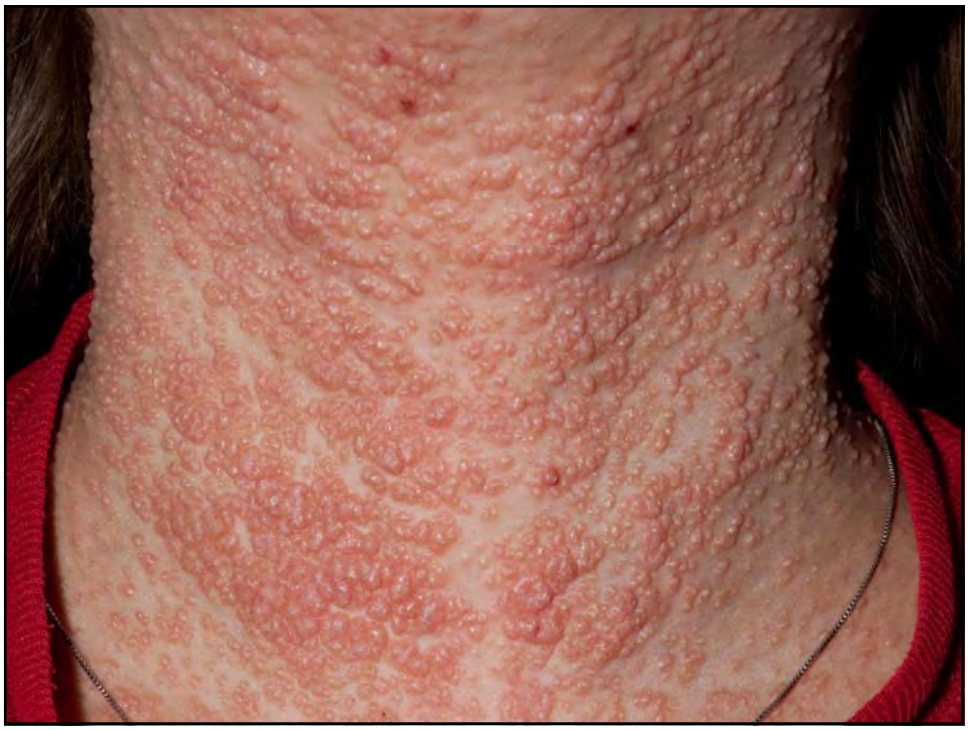

DOCK8 immunodeficiency: HSV infection

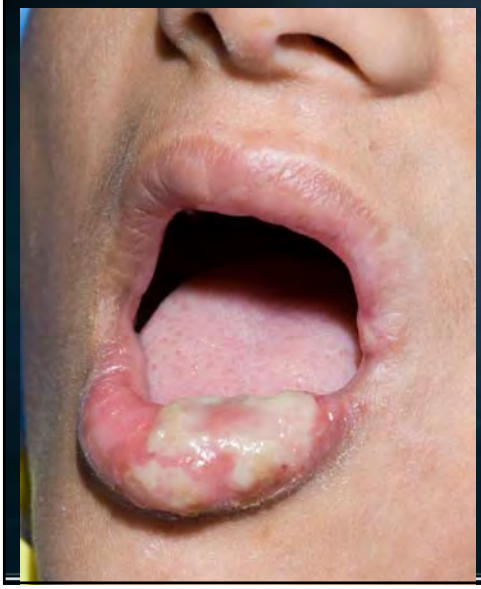

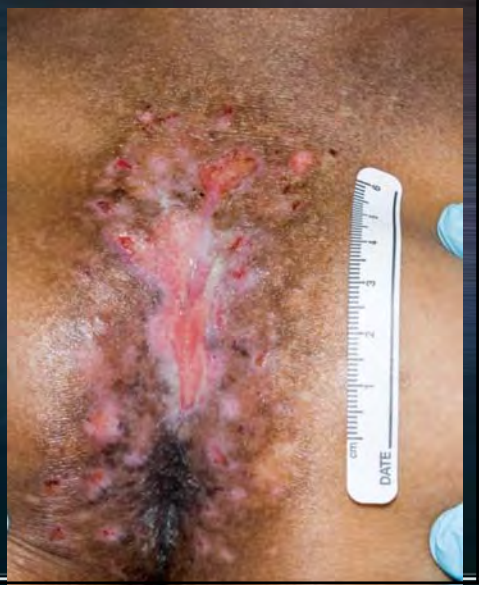

DOCK8 combined immunodeficiency: 20 yo extensive HPV pre/post HSCT

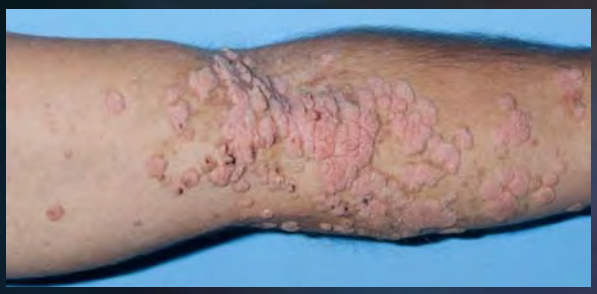

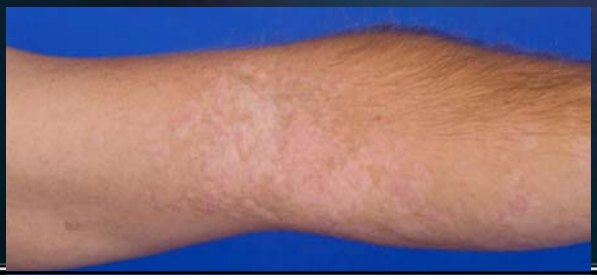

Resolution of refractory HSV gingivitis

Pre-HSCT

Post-HSCT

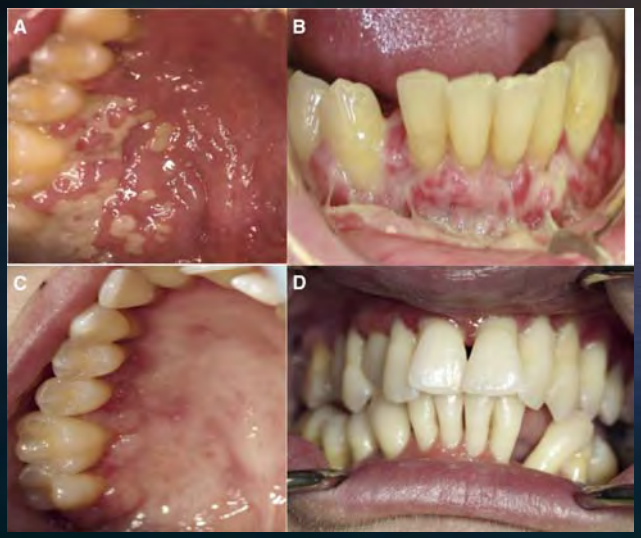

Biology of Blood and Marrow Transplant 2015 21, 1037-1045

Autosomal Dominant Hyper IgE/Job syndrome

- Broad nasal root with fleshy nasal tip
- Coarse features with 'doughy' subcutaneous tissue
- Prominent wide forehead; prognathic pointed chin



Oral Diseases 14; p.73-81. January 2008

nature Vol 448|30 August 2007|doi:10.1038/nature06096

2007;448:1058.

LETTERS

Dominant-negative mutations in the DNA-binding domain of STAT3 cause hyper-IgE syndrome

Yoshiyuki Minegishi[1], Masako Saito[1], Shigeru Tsuchiya[1], Ikuya Tsuge[1], Hidetoshi Takada[1], Toshiro Hara[1], Nobuaki Kawamura[1], Tadashi Ariga[1], Srdjan Pasic[5], Oliver Stojkovic[7], Ayse Metin[8] & Hajime Karasuyama[1]

2007;357:1608.

The NEW ENGLAND JOURNAL of MEDICINE

ORIGINAL ARTICLE

STAT3 Mutations in the Hyper-IgE Syndrome

Steven M. Holland, M.D., Frank R. DeLeo, Ph.D., Houda Z. Elloumi, Ph.D., Amy P. Hsu, B.A., Gulbu Uzel, M.D., Nina Brodsky, B.S., Alexandra F. Freeman, M.D., Andrew Demidowich, B.A., Joie Davis, A.P.R.N., Maria L. Turner, M.D., Victoria L. Anderson, C.R.N.P., Dirk N. Darnell, M.A., Pamela A. Welch, B.S.N., Douglas B. Kuhns, Ph.D., David M. Frucht, M.D., Harry L. Malech, M.D., John I. Gallin, M.D., Scott D. Kobayashi, Ph.D., Adeline R. Whitney, B.A., Jovanka M. Voyich, Ph.D., James M. Musser, M.D., Ph.D., Cristina Woellner, M.Sc., Alejandro A. Schäffer, Ph.D., Jennifer M. Puck, M.D., and Bodo Grimbacher, M.D.

STAT 3

Impaired T_H17 cell differentiation in subjects with autosomal dominant hyper-IgE syndrome

Joshua D. Milner[1]*, Jason M. Brenchley[2]*†, Arian Laurence[3], Alexandra F. Freeman[4], Brenna J. Hill[2], Kevin M. Elias[3,5], Yuka Kanno[3], Christine Spalding[4], Houda Z. Elloumi[4], Michelle L. Paulson[4], Joie Davis[4], Amy Hsu[4], Ava I. Asher[2], John O'Shea[3], Steven M. Holland[4], William E. Paul[1] & Daniel C. Douek[2]

Nature 2008;452:773.

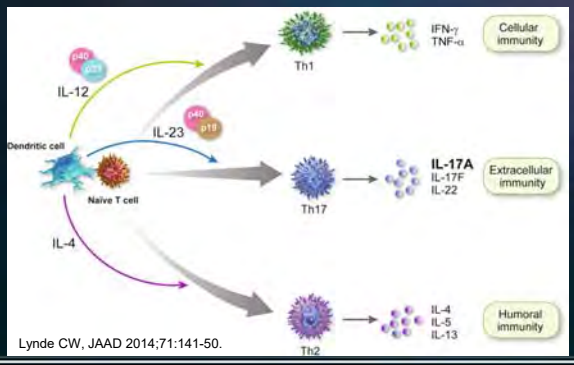

Lynde CW, JAAD 2014;71:141-50.

T_H17 cells

- Differentiation dependent upon *STAT-3* signaling
- Secrete IL-17A, IL-17F, IL-21, IL-22, IL-26
  - Broad range of proinflammatory danger signals
- IL-17A: 155aa glycoprotein
  - Homo- or heterodimer (IL-17F)
  - Restricted expression → activated T-cells
  - No resemblance to other IL or known proteins


Interleukin 17F

T_H17 cells

- Differentiation dependent upon *STAT-3* signaling
- Secrete IL-17A, IL-17F, IL-21, IL-22, IL-26
  - Broad range of proinflammatory danger signals
- IL-17A: 155aa glycoprotein
  - Homo- or heterodimer (IL-17F)
  - Restricted expression → activated T-cells
  - No resemblance to other IL or known proteins

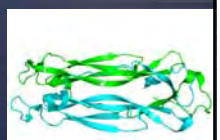
Interleukin 17F

- Mucocutaneous antifungal immunity

Science AAAS

Chronic Mucocutaneous Candidiasis in Humans with Inborn Errors of Interleukin-17 Immunity
Anne Puel, *et al.*
Science **332**, 65 (2011);
DOI: 10.1126/science.1200439

- Autosomal recessive: complete loss of cytokine receptor, interleukin-17 receptor A (IL-17RA)
- Autosomal dominant: impaired activity of cytokine interleukin-17F (IL-17F)

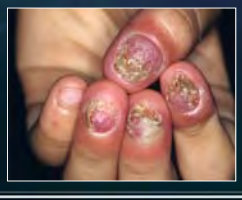

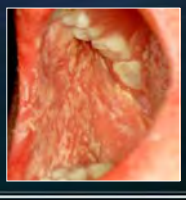

APECED

- Autoimmune polyendocrinopathy, candidiasis, ectodermal dystrophy (APECED)
- Autoimmune regulator gene (*AIRE*)



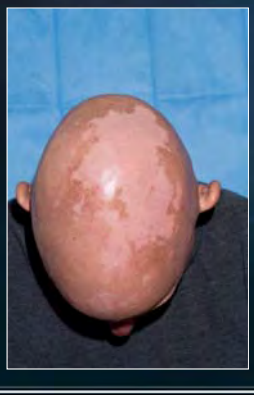

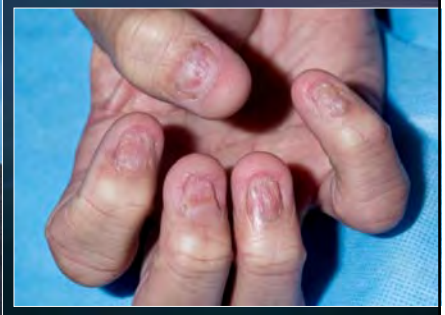

The importance of Th17/IL-17 in PID

Genetic change	Impact on Th17/IL-17 pathway	Clinical impact
IL-17F mutation	IL-17F cellular responses impaired	CMC
IL-17RA deficiency	IL-17A and IL-17F cellular responses abolished*	CMC
AIRE mutation	Autoantibodies against IL-17A, IL-17F, and/or IL-22; diminished responses to Th17 cytokines	Autoimmune polyendocrine syndrome 1, with CMC
STAT1 mutation	Defective Th1 and Th17 responses, with reduced production of IFN-gamma, IL-17A, and IL-22	Autosomal dominant CMC
STAT3 deficiency	Multiple defects, including Th17 lymphopenia	Hyper-IgE syndrome, including CMC and other mucocutaneous infections
CARD9	CARD9 deficiency results in defects in inflammatory cytokine production and fungal killing by phagocytes	CMC
ACT 1 mutations	Impairs IL-17 cytokine receptor subunit interactions	*Candida* infection

Lynde CW, JAAD 2014;71:141-50.

Th17/IL-17 and psoriasis

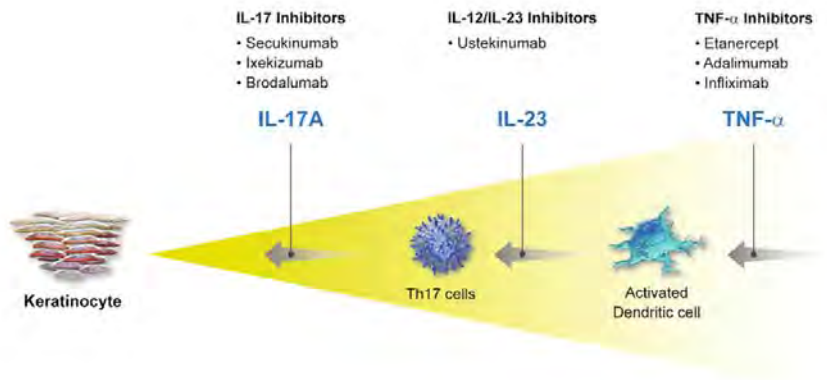

Lynde CW, *et al.* JAAD 2014 Jul;71(1):141-50).

Th17/IL-17 and psoriasis

Table 1. Phase III and Marketed IL-17 or IL-23 Targeting Psoriasis Drugs

DRUG	COMPANIES	PHASE III INITIATION	MAJOR MARKET LAUNCH DATE	TARGET
Stelara (ustekinumab)	J&J	Q4 2005	Q1 2009 (Europe) Q3 2009 (US) Q1 2011 (Japan)	IL-12/IL-23
Cosentyx (secukinumab)	Novartis	Q1 2011	Q4 2014 (Japan) Q1 2015 (US & Europe)	IL-17
ixekizumab	Lilly	Q4 2011	H1 2016 (US predicted)	IL-17
brodalumab	Amgen/AZ/ Kyowa Hakko Kirin	Q3 2012	2016 (US predicted)	IL-17 receptor
tildrakizumab	Merck/Sun Pharma	Q4 2012	H2 2016 (US predicted)	IL-23
guselkumab	J&J/MorphoSys	Q4 2014	2018 (US predicted)	IL-23

Lancet June 10, 2015

Comparison of ixekizumab with etanercept or placebo in moderate-to-severe psoriasis (UNCOVER-2 and UNCOVER-3): results from two phase 3 randomised trials

Christopher E M Griffiths, Kristian Reich, Mark Lebwohl, Peter van de Kerkhof, Carle Paul, Alan Menter, Gregory S Cameron, Janelle Erickson, Lu Zhang, Roberta J Secrest, Susan Ball, Daniel K Braun, Olawale O Osuntokun, Michael P Heffernan, Brian J Nickoloff, Kim Papp, for the UNCOVER-2 and UNCOVER-3 investigators*

Summary

Background Ixekizumab is a humanised monoclonal antibody against the proinflammatory cytokine interleukin 17A. We report two studies of ixekizumab compared with placebo or etanercept to assess the safety and efficacy of specifically targeting interleukin 17A in patients with widespread moderate-to-severe psoriasis.

Published Online June 10, 2015 http://dx.doi.org/10.1016/S0140-6736(15)60125-8

Supplemental Table 9: *Candida* or Suspected *Candida* Infections Pooled Studies

	UNCOVER-2 and UNCOVER-3			
	PBO (N=360)	ETN (N=739)	IXE Q4W (N=729)	IXE Q2W (N=734)
Total, n (%)	2 (0.6)	5 (0.6)	4 (0.5)	12 (1.6)
Oral	0	1 (0.1)	1 (0.1)	6 (0.8)
Genital/vulvovaginal	1 (0.3)	4 (0.5)	3 (0.4)	2 (0.3)
Skin/intertrigo	1 (0.3)	0	0	2 (0.3)*
Otitis externa	0	0	0	1 (0.1)
Oesophageal	0	0	0	1 (0.1)

Lancet June 10, 2015

Comparison of ixekizumab with etanercept or placebo in moderate-to-severe psoriasis (UNCOVER-2 and UNCOVER-3): results from two phase 3 randomised trials

Christopher E M Griffiths, Kristian Reich, Mark Lebwohl, Peter van de Kerkhof, Carle Paul, Alan Menter, Gregory S Cameron, Janelle Erickson, Lu Zhang, Roberta J Secrest, Susan Ball, Daniel K Braun, Olawale O Osuntokun, Michael P Heffernan, Brian J Nickoloff, Kim Papp, for the UNCOVER-2 and UNCOVER-3 investigators*

Summary

Background Ixekizumab is a humanised monoclonal antibody against the proinflammatory cytokine interleukin 17A. We report two studies of ixekizumab compared with placebo or etanercept to assess the safety and efficacy of specifically targeting interleukin 17A in patients with widespread moderate-to-severe psoriasis.

Published Online June 10, 2015 http://dx.doi.org/10.1016/S0140-6736(15)60125-8

[26] Have or had an infection typical of an immunocompromised host, and/or that occurs with increased incidence in an immunocompromised host (including, but not limited to, *Pneumocystis jirovecii* pneumonia, histoplasmosis, or coccidioidomycosis); or have a known immunodeficiency.

Case

- "Healthy" 23 year old female evaluated for verruca since age 9
- 1 year post-partum, MBA student

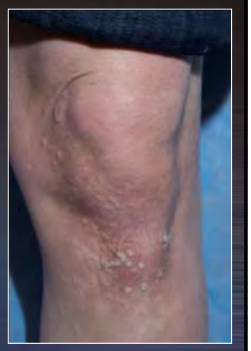

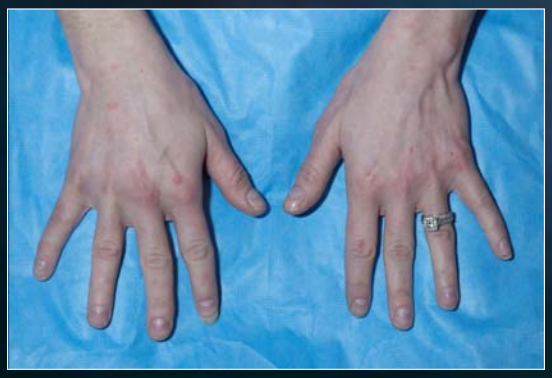

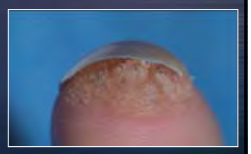

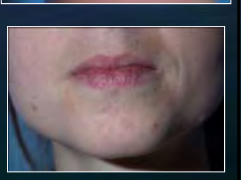

Case

- Imiquimod, cimetidine, squaric acid, laser Tx, LN2, tretinion
- Treated in past with isotretinoin → improvement
- ? Report of low Ig
- Hx of VIN2/3, CIN2 (age 20)
- Hx of recurrent otitis media, arm/leg cellulitis
- Fam Hx: father → warts; maternal family hx leukemia (great aunt, g-mother, 2nd cousin)

GATA2 deficiency: "MonoMAC"

Autosomal dominant and sporadic monocytopenia with susceptibility to mycobacteria, fungi, papillomaviruses, and myelodysplasia

*Donald C. Vinh,[1] *Smita Y. Patel,[1] Gulbu Uzel,[1] Victoria L. Anderson,[1] Alexandra F. Freeman,[1,2] Kenneth N. Olivier,[1] Christine Spalding,[1] Stephen Hughes,[3] Stefania Pittaluga,[4] Mark Raffeld,[4] Lynn R. Sorbara,[5] Houda Z. Elloumi,[1] Douglas B. Kuhns,[6] Maria L. Turner,[7] Edward W. Cowen,[7] Danielle Fink,[6] Debra Long-Priel,[6] Amy P. Hsu,[1] Li Ding,[1] Michelle L. Paulson,[1] Adeline R. Whitney,[8] Elizabeth P. Sampaio,[1] David M. Frucht,[9] Frank R. DeLeo,[8] and Steven M. Holland[1]

Blood. 2010;115(8):1519-29.

1. Profound monocytopenia (B, NK-penia)
2. Non-Tb mycobacteria, HPV, fungal infections
3. 10/18 malignancy
   - MDS/leukemia (9), vulvar CA, metastatic melanoma, Bowens, leiomyosarcoma

Emberger S.

- Primary lymphedema
- SN hearing loss
- AML

- HPV infection
- Anogenital dysplasia

nature genetics
43: 929–931 (2011)

Mutations in *GATA2* cause primary lymphedema associated with a predisposition to acute myeloid leukemia (Emberger syndrome)

GATA2-related syndrome	Immunologic findings	Infections	Other clinical findings
Monocytopenia and mycobacterial infection (MonoMac) syndrome	Monocyte, B, and NK cell lymphopenia	Mycobacterial Fungal Viral	Pulmonary alveolar proteinosis Erythema nodosum Lymphedema Myelodysplasia Myeloid leukemia
Dendritic cell, monocyte, B, and NK lymphocyte (DCML) deficiency	Dendritic cell, monocyte, B and NK cell lymphopenia	Mycobacterial Viral	Pulmonary alveolar proteinosis Myelodysplasia Myeloid leukemia
Familial myelodysplastic syndrome/acute myeloid leukemia	Multilineage cytopenia		Myelodysplasia Myeloid leukemia
Emberger syndrome	Variable multilineage cytopenia	Viral	Congenital sensorineural hearing loss Lower limb and genital primary lymphedema Anogenital dysplasia Myelodysplasia Myeloid leukemia

Pichard *et al.* J Am Acad Dermatol *(in press)*

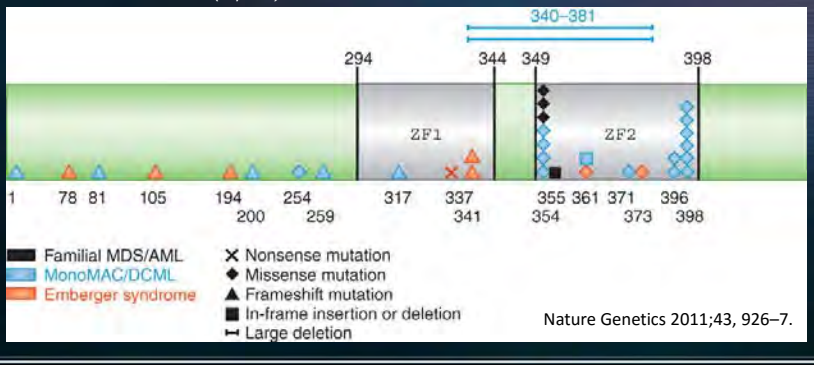

Nature Genetics 2011;43, 926–7.

GATA 2 deficiency

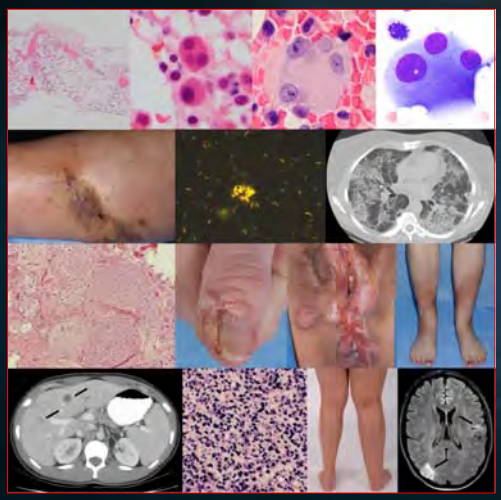

Spinner *et al.* Blood 2014;123:809-21.

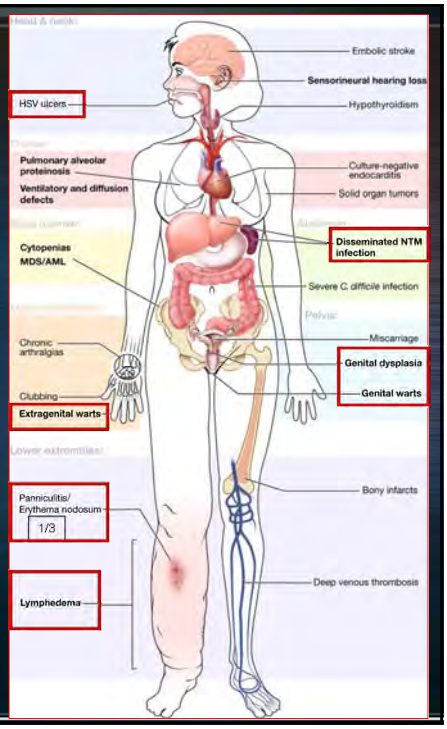

GATA2 deficiency: NIH cohort

- 57 patients (1992-2013)
  - 51% symptomatic by age 20
  - 42/50 bone marrow → MDS (hypocellular)
  - Infections
    - HPV: 63%
    - HSV1/2: 16%, severe VZV: 11%, EBV: 11%, CMV: 4%
    - Atypical mycobacterial: 53% (slow and rapid)
    - Bacterial: 49% (bacteremia 21%, skin/soft tissue 19%, *C. difficile* colitis 9%)
    - Fungal: 16% (aspergillosis 9%, histoplasmosis 5%)

Blood 2014;123:809-21.

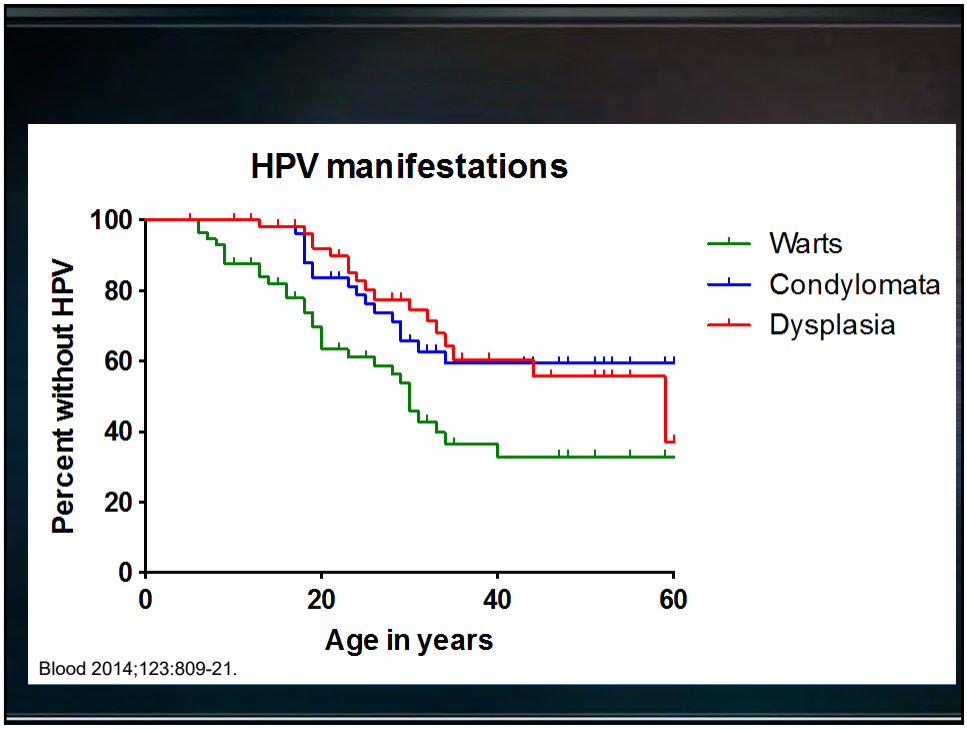

Monomac: Abscess, HPV, VIN III, AIN II

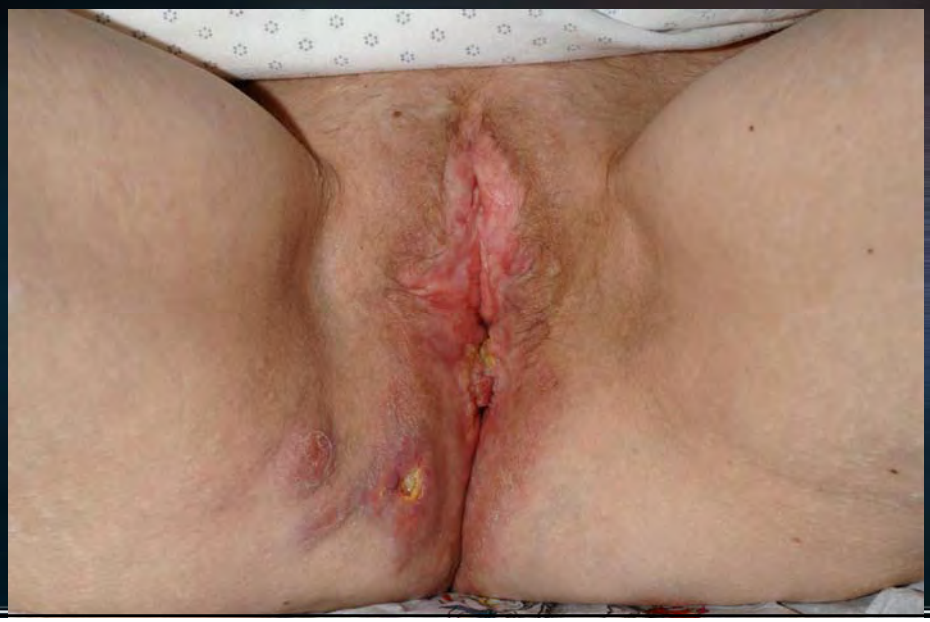

Monomac: MAI, panniculitis, VIN

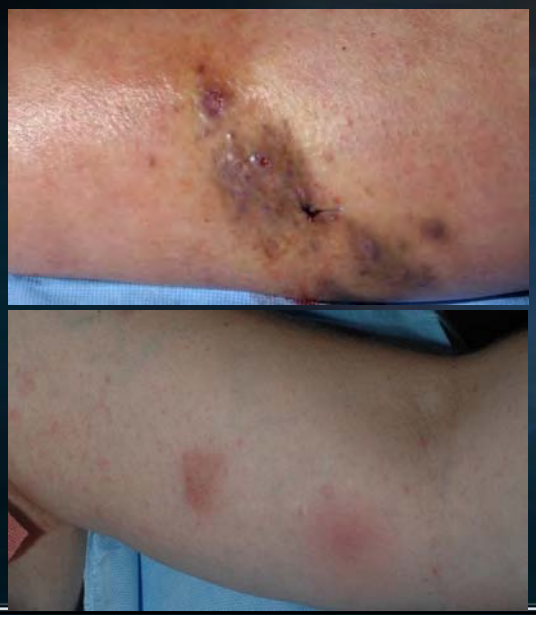

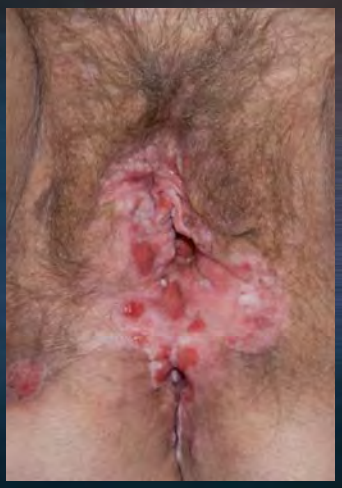

GATA2 lymphedema

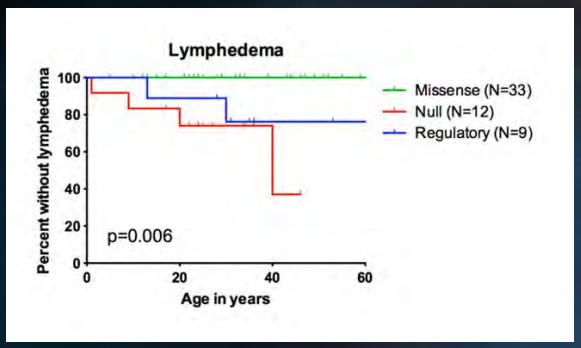

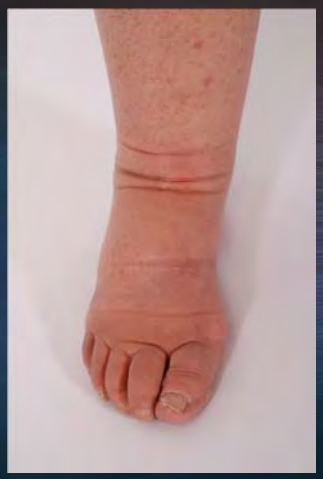

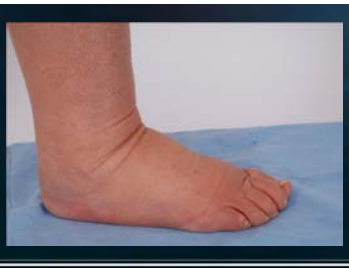

GATA2 lymphedema

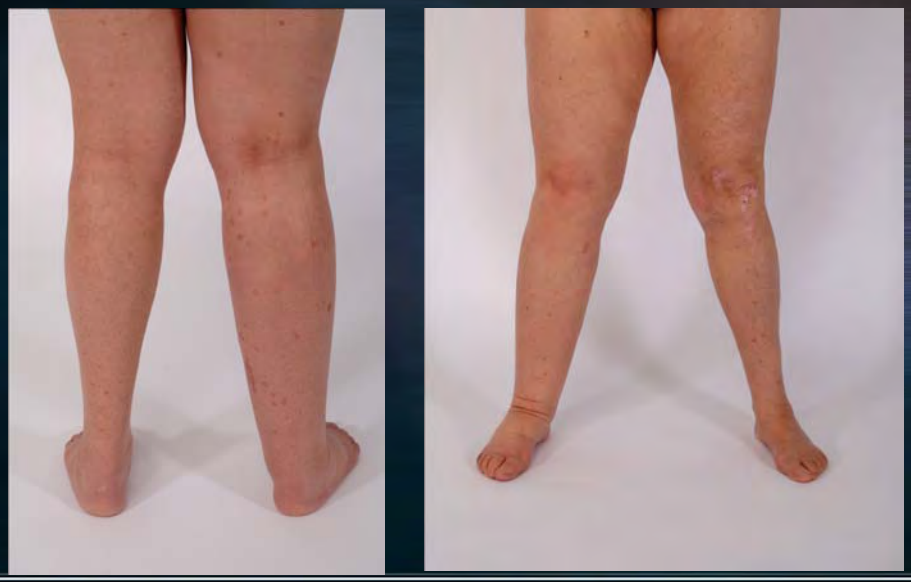

Case: follow-up

- Presented at NIH Derm Rounds Feb 2013
  - CBC: 0.05 monocytes (0.24-0.86K/uL)
  - Peripheral blood: 8-10% blasts
  - Bone marrow: 15% blasts (MDS/AML)
  - Dx: GATA2/Monomac w/ MDS/AML
- March 2013: induction chemoTx (ARA-C, idarubicin)
- April 2013: 28% circulating blasts (2nd induction)
- May 2013: Allogeneic HSCT (unrelated donor)
- June 2013: Stage IV skin, liver, gut GVHD→ deceased

Do you have a pt. with GATA2 deficiency?

- Aggressive HPV, lymphedema, MDS/AML, infection hx
- B, NK, monocytopenia → strongly suggestive of GATA2 deficiency
- Other undefined PIDs
- Pediatric MDS/JMML (8/51)
  - Blood ASH Abstracts 2012:1699.
- Idiopathic CD4+ lymphocytopenia (6/14)
  - Blood 2013;121:822-9.
- Aplastic anemia (5/99)
  - Blood ASH Abstracts 2012;3488.

Acknowledgements

- DOCK8, STAT3, STAT1
  - Alexandra Freeman
  - Steve Holland
- APECED
  - Michail Lionakis
- GATA2
  - Steve Holland
  - Christa Zerbe

New manifestation of an old immunodeficiency

ADA-SCID associated DFSPs

Adenosine deaminase

- Convert adenosine to inosine and 2'-deoxyadenosine to 2'-deoxyinosine
- ADA-SCID
  - Toxic intracellular accumulation of deoxyadenosine
  - Profound B/T cell lymphopenia, recurrent infection
  - Lethal in childhood
  - Tx: Pegylated-ADA1, gene therapy

CLINICAL IMMUNOLOGY AND IMMUNOPATHOLOGY
Vol. 76, No. 3, September, pp. S228–S232, 1995

PEG-ADA Replacement Therapy for Adenosine Deaminase Deficiency: An Update after 8.5 Years[1]

MICHAEL S. HERSHFIELD

Departments of Medicine and Biochemistry, Duke University Medical Center, Durham, North Carolina 27707

The NEW ENGLAND JOURNAL of MEDICINE

ESTABLISHED IN 1812 JANUARY 29, 2009 VOL. 360 NO. 5

Gene Therapy for Immunodeficiency Due to Adenosine Deaminase Deficiency

ADA-SCID enzyme replacement/survival

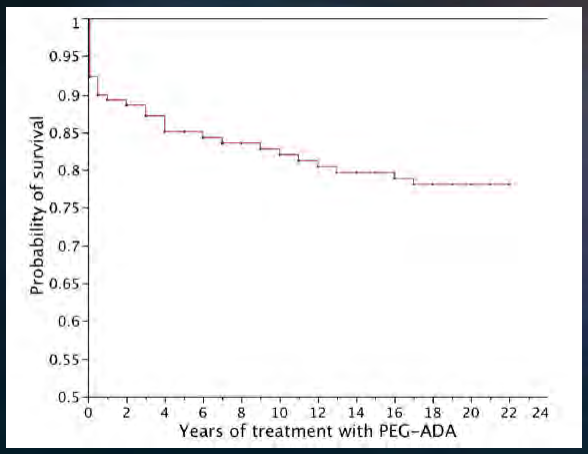

Blood. 2009;114(17):3524-32.

DFSP in ADA-SCID

- 2 pediatric ADA-SCID pts (ages 2 and 3): dermatofibrosarcoma protuberans (DFSP)
  - Giant cell fibroblastoma (GCF)
  - One pt. with <u>multiple</u> atrophic DFSPs

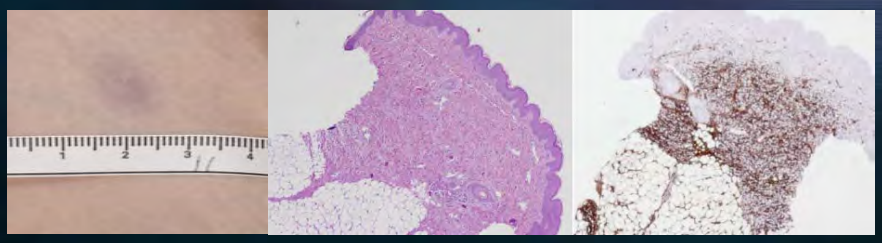

DFSP H & E CD34

Multicentric dermatofibrosarcoma protuberans in patients with adenosine deaminase–deficient severe combined immune deficiency

Chimene Kesserwan, MD,[a*+]; Robert Sokolic, MD,[a*] Edward W. Cowen, MD,[b] Elizabeth Garabedian, MSc,[a] Kerstin Heselmeyer-Haddad, PhD,[c] Chyi-Chia Richard Lee, MD, PhD,[d] Stefania Pittaluga, MD,[d] Clarymar Ortiz, BSc,[e] Kristin Baird, MD,[a] Dolores Lopez-Terrada, MD, PhD,[f] Julia Bridge, MD,[g] Alan S. Wayne, MD,[a] and Fabio Candotti, MD[a] *Bethesda, Md, Houston, Tex, and Omaha, Neb*

J Allergy Clin Immunol 2012 Mar;129(3):762-769.

- Single DFSP lesions described in two ADA-SCID pts.
  - DFSP: Rubocki *et al. Blood*. 2001;97:809-81
  - GCF: Carroll D *et al. Pediatr Surg Int.* 2003;19:495-6
- Evaluation of 10 additional ADA-SCID pts: DFSP 8/12
  - 6/12 pts. multiple Bx-proven DFSP: 54 total tumors
  - Atrophic, lack classic storiform histology
  - Immunohistochemistry: CD34+, XIIIa-
  - Cytogenetic/molecular confirmation
    - Karyotype t(17;22)(q21.3;q13.1)
    - FISH: COL1A1-PDGFB fusion
    - RT-PCR: COL1A1-PDGFB transcript

6 year old boy with ADA-SCID, DFSP

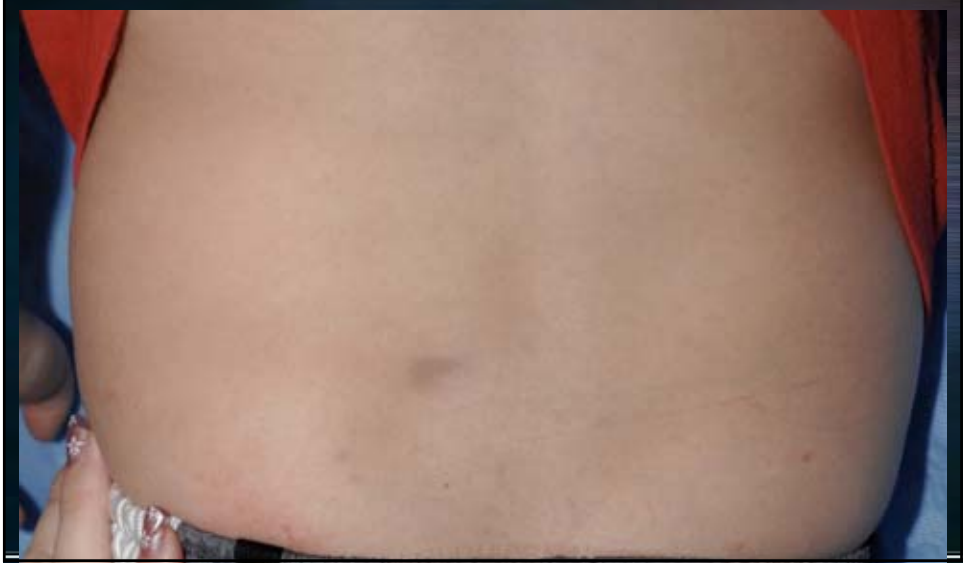

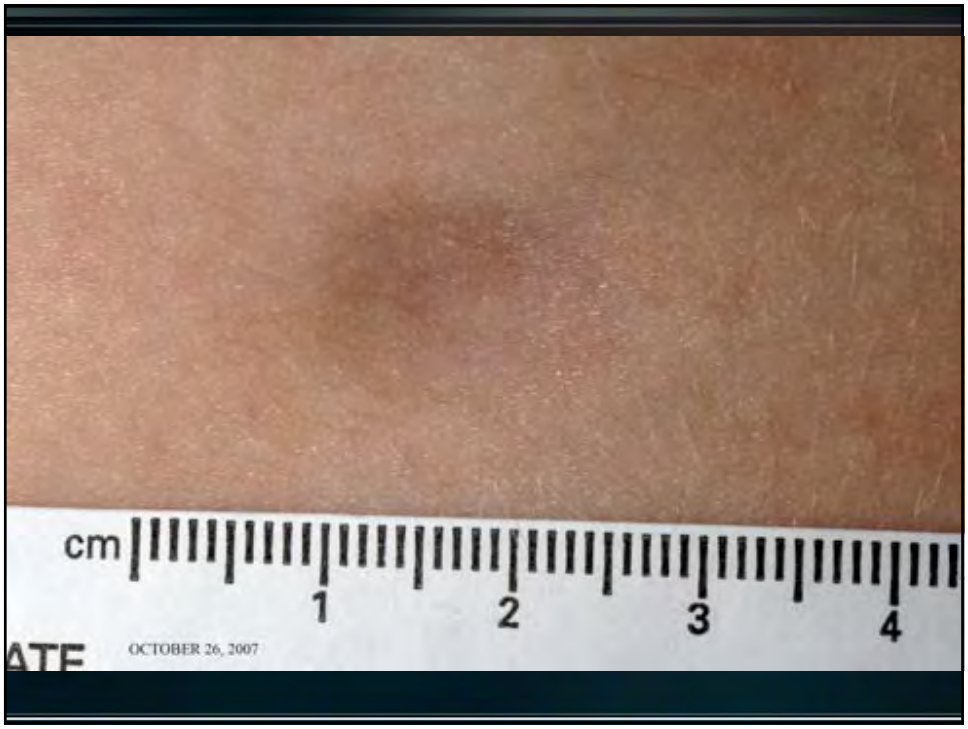

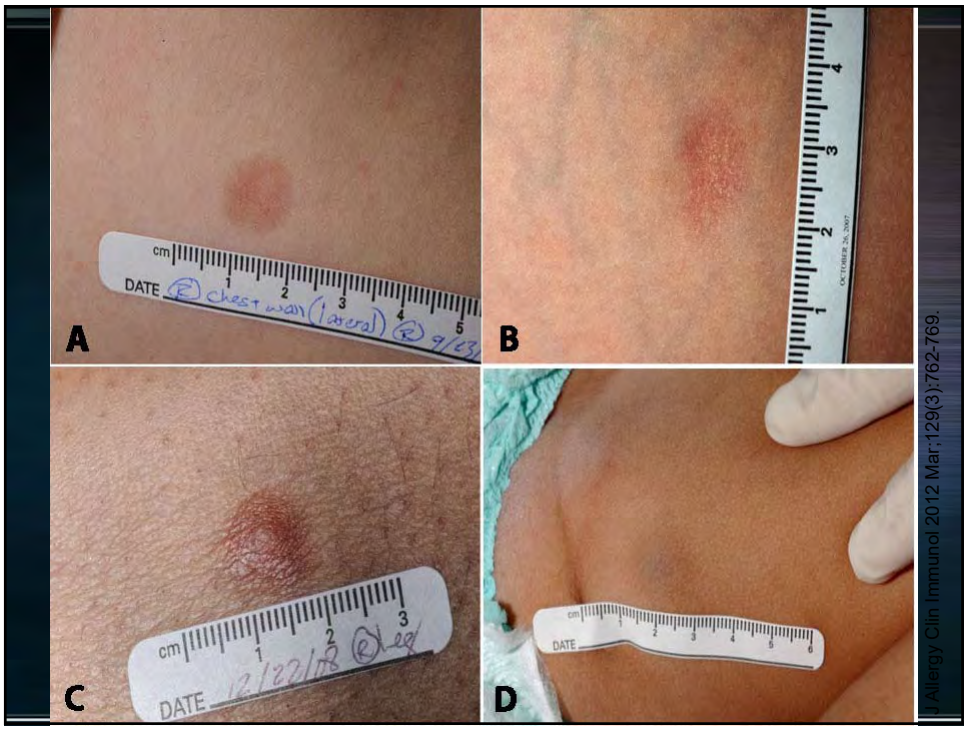

J Allergy Clin Immunol 2012 Mar;129(3):762-769.

DFSP: FISH

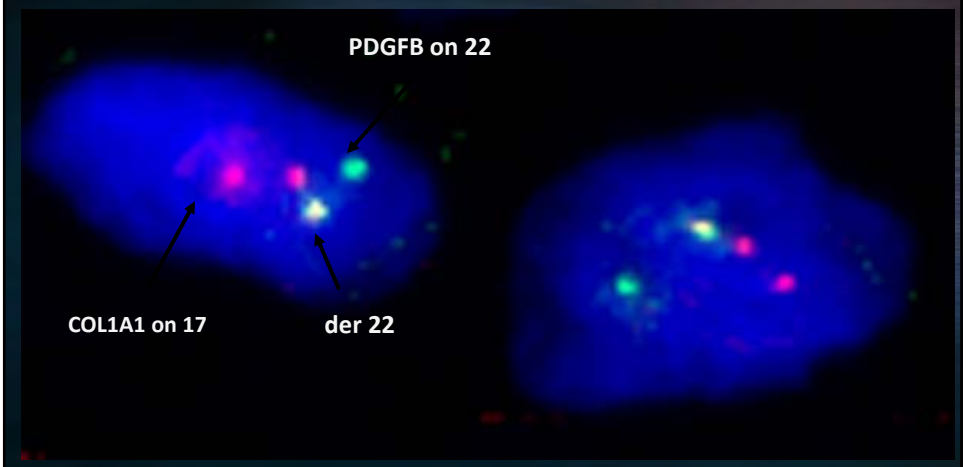

Unanswered questions

- Link between T-cell immunosuppression, failure of immune surveillance, and DFSP?
- Unidentified virus?
  - HHV-8: Kaposi sarcoma
  - Merkel cell polyomavirus: Merkel cell carcinoma
- Natural history of DFSP in ADA-SCID setting?
  - Imatinib mesylate?

Advances in PID and skin disease

- Genetic advances → understanding of immunity in healthy and disease states
- Therapeutic advances
  - Antimicrobial prophylaxis
  - Gene therapy
  - Hematopoietic stem cell transplantation
  - Altered natural history of disease
    - Cardiac disease in Job syndrome
    - DFSP in ADA-SCID